



Disseminated Intravascular Coagulation

Yaron Bruchim, DVM
 Itamar Aroch, DVM, DECVIM-CA
 Joseph Saragusty, DVM
 The Hebrew University of Jerusalem, Israel

Trevor Waner, BVSc, PhD, DECLAM
 Israel Institute for Biological Research, Ness Ziona, Israel

ABSTRACT: Disseminated intravascular coagulation (DIC) is a serious, life-threatening condition in humans and animals. A secondary complication in a variety of disorders, it is a complex syndrome in which excessive intravascular coagulation leads to microthromboses in and consequential failure of multiple organs with concurrent paradoxical bleeding due to inactivation and excessive consumption of platelets and clotting factors. This article discusses the pathophysiology, diagnosis, and treatment of DIC in dogs and cats. Novel treatments and laboratory tests, some of which are still being experimentally evaluated, are also discussed.

Disseminated intravascular coagulation (DIC) is a serious, life-threatening complication in humans and animals, previously called *consumptive coagulopathy* or *defibrination syndrome*.¹ In this complex syndrome, excessive intravascular coagulation leads to diffuse microthromboses and subsequent failure of multiple organs. Inactivation and excessive consumption of platelets and clotting factors cause concurrent paradoxical bleeding. DIC is not a primary disease but rather a secondary complication of several disorders¹⁻³ (Box 1). Moreover, it constitutes a dynamic phenomenon during which the patient's status and laboratory coagulation test results may fluctuate markedly, rapidly, and repeatedly. It is relatively common in dogs and uncommon in cats.⁴

PATHOPHYSIOLOGY

In healthy animals, the normal mechanisms of clot formation and fibrinolysis are well balanced

so that coagulation and clot formation occur only on demand. In DIC, this balance is disrupted, leading to concurrent excessive clot formation and bleeding (Figure 1). Thus, DIC may be considered as an uncontrollable burst of thrombin generation and activation resulting in systemic fibrin formation, plasmin activation, suppression of the physiologic anticoagulation mechanisms, and delayed fibrin removal as a consequence of impaired fibrinolysis.^{5,6} During this excessive intravascular coagulation phase, platelets and coagulation factors are consumed, resulting in thrombocytopenia, thrombocytopeny, and depletion and inactivation of coagulation factors.⁶⁻⁸

DIC is an acquired syndrome that occurs as a result of a primary disorder. Three factors, commonly termed *Virchow's triad*, predispose patients to thrombosis: stasis, hypercoagulability, and blood vessel wall injury.⁹ Therefore, any disease process that results in capillary stasis, loss of

Box 1. Clinical Conditions Potentially Associated with DIC**Systemic bacterial infections/sepsis**

- Gram-negative bacteria (endotoxin)
- Gram-positive bacteria (bacterial coat mucopolysaccharide, enzymes)

Viral diseases

- Canine parvovirus
- Infectious canine hepatitis
- Feline panleukopenia
- FIP

Canine parasitic and rickettsial infections

- Babesiosis (*Babesia canis rossi*)
- Monocytic ehrlichiosis (*Ehrlichia canis*) and Rocky Mountain spotted fever (*Rickettsia rickettsii*)
- Leishmaniasis (*Leishmania infantum*)
- Spirocerosis (*Spirocerca lupi*)
- Heartworm disease (*Dirofilaria immitis*)
- Caval syndrome (*Angiostrongylus vasorum* and *Dirofilaria immitis*)

Neoplasia

- Solid tumors (e.g., mammary tumors)
- Lymphoid leukemia
- Myeloproliferative disorders
- Lymphoma
- Hemangiosarcoma (canine)
- Pulmonary adenocarcinoma

Immunologic disorders

- Immune-mediated hemolytic anemia
- Hemolytic transfusion reaction
- Transplant rejection

Vascular disorders

- Aortic aneurysm
- Vasculitis
- Hemangioma

Massive tissue injury

- Heatstroke and hyperthermia
- Gastric dilatation-volvulus (canine)
- Burns
- Head trauma
- Fat embolism
- Surgery (especially extensive and orthopedic)
- Severe mechanical trauma

Reaction to toxins

- Snakebite

Miscellaneous

- Pancreatitis
- Polycythemia
- Hepatic failure

vascular integrity, or hypercoagulability (e.g., the presence of inappropriate matter in the bloodstream, tissue necrosis) can lead to disruption of the balance between hemostasis and fibrinolysis and subsequently induce DIC.^{5,8} Depending on the activation rate of the hemostatic system, DIC may present on the one extreme as a peracute, life-threatening clinical event and on the other as a chronic condition with no overt hemorrhage or thrombosis.^{5,8,10,11}

Many common systemic diseases associated with inflammation have been reported to initiate DIC in dogs and cats^{12–17} (Box 1). In a recent study¹³ that included 164 dogs with solid tumors, 12.2% of the dogs presented with DIC, and dogs with hemangiosarcoma, mammary gland carcinoma, or pulmonary adenocarcinoma had a significantly higher incidence of DIC. In another study¹² of 54 dogs with heatstroke, 50% presented with DIC.

Regardless of whether the intrinsic or extrinsic activation pathway is initiated, once triggered, DIC follows the same course. Only recently has the importance of the inflammatory mechanism in the up-regulation of procoagulant factors been recognized. This up-regulation results in increased thrombin generation, systemic fibrin formation, down-regulation of natural anticoagu-

lants, and delayed fibrin removal as a consequence of inadequate fibrinolysis.^{18,19} In addition, inflammation tends to lead to an increase in fibrinogen levels, unless fibrinogen consumption is concurrent.^{20,21} In sepsis or inflammation, the propagation of the coagulation cascade is also promoted by a reduction in the physiologic anticoagulation activity. With extensive clot formation, antithrombin (AT) is consumed by binding in a one-to-one fashion with each clotting factor. Moreover, the presence of endotoxin or inflammatory mediators reduces the endothelial expression of glycosaminoglycans, such as heparan sulfate, that normally augment the activity of AT, leading to reduced AT activity and endothelial antithrombotic function^{22–26} (Figure 2).

Generation of Thrombin

The systemic generation of thrombin in animal models of DIC is mediated exclusively by the extrinsic pathway, involving tissue factor and activated factor VII (VIIa).¹⁸ Levi and colleagues²⁷ showed that inhibition of tissue factor or factor VIIa totally suppressed the endotoxin-induced generation of thrombin, whereas interference in the intrinsic pathway of coagulation did not affect the activation of coagulation.

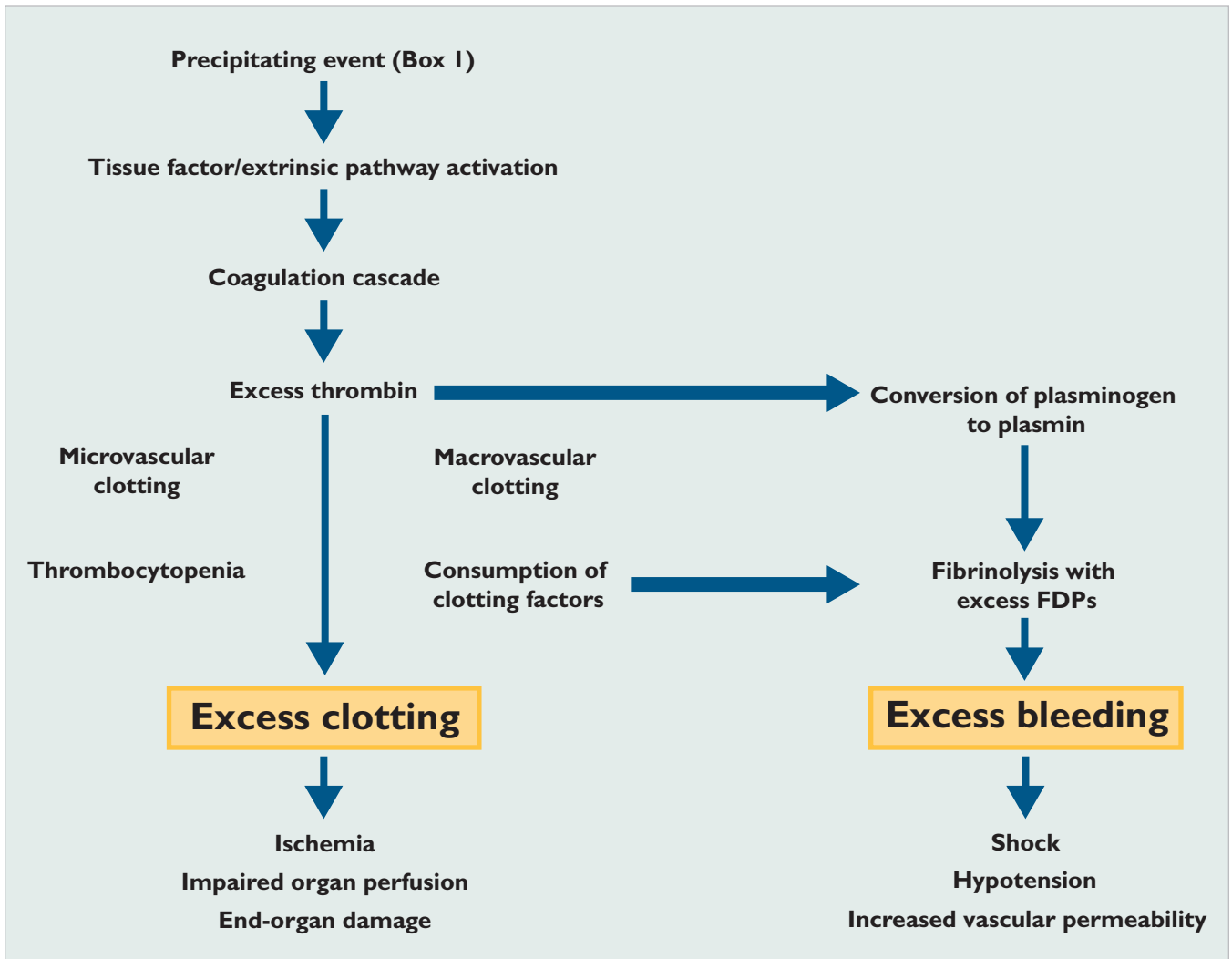


Figure 1. Mechanisms leading to the development of DIC. FDP = fibrin degradation products. (Adapted from Gobel BH. Disseminated intravascular coagulation in cancer: providing quality care. *Topics Adv Pract Nurs J* [online] 2002;2(4). Accessed October 2008 at www.medscape.com)

The conditions that lead to DIC are the same as those associated with systemic inflammatory response syndrome and are characterized by activation of cytokine production. The principal mediators are interleukins 1 and 6 and tumor necrosis factor (TNF), which are released from the monocyte–macrophage system.^{8,18,28,29} These cytokines stimulate macrophages to express several procoagulant moieties (mainly tissue factor) on their outer surface.^{21,29} The reactions involved in coagulation initiation and amplification require a membrane surface that contains negatively charged phospholipids. Normally, these negatively charged phospholipids are not expressed on cell surfaces in sufficient concentrations for initiation and

propagation of the coagulation cascade to take place. To express the optimal procoagulant lipid surface, potent cell agonists, such as a combination of collagen and thrombin, are required.³⁰ In addition, increased interleukin-1 levels have been shown to increase platelet reactivity and thrombogenic potential.³¹

Impairment of Fibrinolysis and the Role of Fibrin Degradation Products

Studies in animal models of DIC indicate that the fibrinolytic system is largely suppressed when coagulation is maximally activated. This inhibition is caused by up-regulation and a sustained increase in the plasma level of

plasminogen activator inhibitor, the principal inhibitor of the fibrinolytic system, as well as depression of tissue plasminogen activator production.^{8,27,32} Fibrin deposition forms multiple microthrombi within small blood vessels, leading to tissue ischemia and necrosis in vital organs.^{7,33} Although the fibrinolytic system is largely activated through the actions of thrombin, as evidenced by increased plasma levels of plasmin- α_2 -antiplasmin (PAP) complexes, fibrinogen degradation products (FDPs), and D-dimers as well as a concurrent decrease in plasminogen levels, the degree of fibrinolysis is too low to counteract the massive systemic fibrin deposition.³⁴⁻³⁸ During the acute inflammatory response and the initiation of DIC, this inadequacy is exacerbated by the increased plasma concentrations of the protease inhibitors α_2 -macroglobu-

lin and α_1 -antitrypsin (also known as α_1 -*proteinase inhibitor*), both of which inhibit coagulation as well as fibrinolysis.³⁹ In patients with pancreatitis, the excessive release of active trypsin into the bloodstream culminates in a marked depletion of protease inhibitors,⁴⁰ leading to overt coagulation and fibrinolysis.

The systemically circulating FDPs interfere with fibrin monomer polymerization, leading to further impairment of hemostasis and potential hemorrhage. FDPs, especially fragments D and E, are strong inhibitors of platelet function and, when present in sufficient quantities, coat platelet surfaces and induce platelet dysfunction.^{41,42} Fibrin-related materials, including FDPs, are normally metabolized by the liver; failure of the liver to clear them from the bloodstream may therefore lead to development of DIC or to worsening of an existing condition.⁴³ Liver failure is a common complication in DIC due to a combination of microthrombosis, anemia, bleeding, and hypoxia; conversely, patients with primary hepatic failure are prone to develop DIC due to the liver's main role in the production of hemostatic proteins.

activated protein C (APC), and tissue factor pathway inhibitor (TFPI), which are all consumed during this phase.^{18,21,29} AT, when combined with heparin, is a potent inhibitor of thrombin and factor Xa and inactivates factors XIIa, XIa, IXa, and VIIa; plasma kallikrein; and plasmin.⁴⁴⁻⁴⁶ Thus, under normal conditions, the activity of the AT-heparin complex controls the coagulation mechanisms and prevents excessive fibrin clotting. However, in DIC, plasma AT levels are markedly reduced as a result of ongoing consumption, degradation by elastase released from activated neutrophils, and impaired synthesis.^{6,8} Thus, coagulation becomes excessive and uncontrolled.

Disseminated intravascular coagulation is characterized by excessive intravascular coagulation leading to diffuse microthromboses and multiorgan failure. Bleeding occurs concurrently due to excessive inactivation and consumption of platelets and clotting factors.

APC is an important regulator of microvascular coagulation and inflammation.⁴⁷ It is an endothelial cell-based protein activated by thrombomodulin-bound thrombin and through binding to the cofactor protein S. APC prevents amplification of procoagulant activity by inactivating factors Va and VIIIa and enhances fibrinolysis through inhibition of plasminogen activator inhibitor.⁴⁷⁻⁴⁹ The protein C pathway appears to be more negatively influenced by inflammation than all other natural anticoagulants. Endothelial cell thrombomodulin and protein C receptor are down-regulated by inflammatory cytokines such as TNF- α .^{50,51} In a canine model of DIC, APC activity decreased after injection of endotoxin.⁵² APC's main function in preventing excessive coagulation during inflammation is exemplified by the fact that APC prevented organ damage in experimental models of sepsis by limiting leukocyte and cytokine elaboration and microvascular coagulation.^{52,53} Thus, marked impairment of APC activity during DIC promotes tissue damage, exacerbates the inflammatory and procoagulant mechanisms contributing to DIC, and further compromises the regulation of activated coagulation.^{2,6,47} In DIC, APC activity is decreased by a combination of impaired synthesis, a cytokine-mediated decrease in endothelial thrombomodulin expression, and a decline in levels of protein S.^{6,47}

Inhibition and Consumption of Natural Anticoagulants

Excessive intravascular coagulation results in reduction and down-regulation of the natural anticoagulants AT,

CLINICAL SIGNS

Dogs with DIC may present with a variety of clinical signs. Three phases of DIC are recognized: the peracute

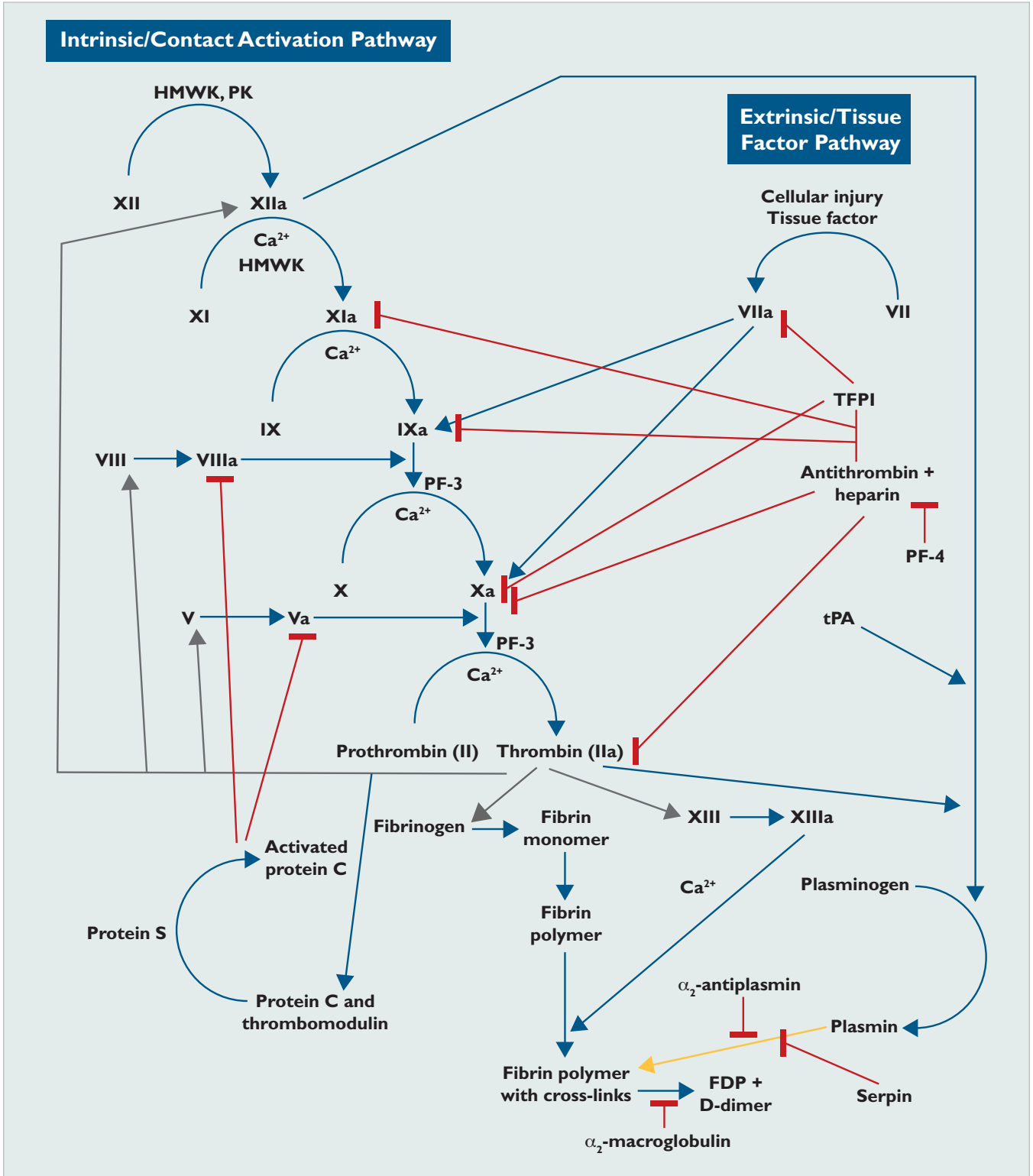


Figure 2. Contact activation (intrinsic) and tissue factor (extrinsic) coagulation pathways and fibrinolytic pathways. Conversion or activation of factors is indicated by blue arrows, inhibition actions by red arrows, actions of thrombin by gray arrows, and lytic actions by yellow arrows. *HMWK* = high molecular weight kininogen, *PF* = platelet factor, *PK* = prekallikrein, *Serpin* = serine protease inhibitor, *TFPI* = tissue factor pathway inhibitor

hypercoagulable phase, the acute consumptive phase, and the chronic silent phase.^{1,44,54} The hypercoagulable and chronic silent phases are nonovert. The latter phase appears to be common in dogs with malignancy and other chronic disorders.⁷ The peracute hypercoagulable and acute consumptive phases may result from an acute, severe disorder (e.g., heatstroke, electrocution, acute pancreatitis) or may follow acute decompensation of chronic silent DIC.⁷ Acute DIC is extremely rare in cats.^{7,33,44}

Regardless of the pathogenesis, dogs with acute DIC often present with profuse spontaneous bleeding, either primary (petechiae, ecchymoses, hematochezia, melena, hematemesis, hematuria) or secondary (blood in body cavities) in concert with hemostatic disorders, and constitutional signs secondary to anemia and to parenchymal organ dysfunction due to diffuse microthromboses.^{5,7,8,18} However, the clinical signs may be highly variable, depending on the underlying primary disease and the phase of DIC (i.e., the balance between throm-

bosis and hemorrhage). Most cats with DIC do not show evidence of spontaneous bleeding; their clinical signs are often those associated with the primary disease.^{7,44,55}

LABORATORY DIAGNOSIS

The diagnosis of DIC is complex and is based on the history, a complete physical examination, knowledge and recognition of the primary conditions associated with DIC, and serial laboratory test results.^{56,57} Several routine hematology findings, although nonspecific, may support a presumptive diagnosis of DIC. These include hemoglobinemia (a result of intravascular hemolysis or tissue necrosis) as well as neutrophilia and neutropenia with a left shift (associated with numerous inflammatory, immune-mediated, and neoplastic disorders). Parenchymal organ thrombosis and subsequent tissue ischemia may lead to increased serum activity of tissue enzymes (e.g., lactate dehydrogenase, alanine aminotransferase, aspartate aminotransferase, creatine kinase), azotemia, hypoxemia, and metabolic acidosis.^{12,15,58,59}

Coagulation Tests

There is no uniformly accepted clinical and laboratory definition of DIC in veterinary medicine; however, it has been suggested that a diagnosis of DIC should rely on the presence of a compatible history and clinical signs as well as at least three abnormal results in the laboratory tests that assess hemostasis.⁶⁰ Several tests for the evaluation of coagulation are available.

Traditionally, a series of laboratory tests is conducted when DIC is suspected. The tests include a platelet count, examination of a blood smear for schistocytes, prothrombin time (PT), activated partial thromboplastin time (aPTT), and AT, fibrinogen, FDP, and D-dimer levels (Table 1).^{56,61} However, the results should always be interpreted with caution and in light of the history and clinical signs because no single test is specific for the diagnosis of DIC. The results of these tests may be abnormal in patients with other diseases or conditions, such as rodenticide anticoagulant intoxication

The clinical signs of disseminated intravascular coagulation include profuse primary or secondary spontaneous bleeding in concert with hemostatic disorders. The constitutional signs are secondary to anemia or to multiorgan dysfunction due to parenchymal organ thromboses.

(prolonged PT and aPTT), thrombotic disease (decreased AT, elevated plasma D-dimers), and liver failure (hypofibrinogenemia, decreased AT, increased plasma FDPs and D-dimers, prolonged PT and aPTT). Furthermore, these tests are not very sensitive markers of DIC because many yield results within the reference range during the early hypercoagulable phase of DIC.

Serial laboratory testing is useful and may be necessary to assess trends in patients suspected to have DIC. In several studies^{10,28,35} of canine DIC, thrombocytopenia was the most common abnormality detected (80% to 100% of cases). Prolonged PT and aPTT ($\geq 25\%$ of the reference range) were detected in 42% to 82% and 67% to 82% of cases, respectively. Increased FDPs and decreased AT activity were detected in 64% to 92% and 67% to 69% of canine DIC cases, respectively.^{8,35,52} In a single retrospective study⁴⁴ of hemostatic disorders in 21 cats with DIC, prolongation of the aPTT was the most common abnormality (100% of cases), followed by prolonged PT (71%) and thrombocytopenia (57%). Increased FDPs and hypofibrinogenemia were detected

in 24% and 5% of the cats, respectively. These data may be biased because the patients in these studies may have been included based on their having abnormalities that met the criteria for diagnosis of DIC.

Hematology and coagulation measures relevant to DIC have been studied in cats with experimentally induced FIP.^{62,63} In one study,⁶³ DIC was induced in kittens by the inoculation of FIP virus. Thrombocytopenia, hyperfibrinogenemia, and increased FDPs were present in all cats after the onset of clinical disease. Plasma activities of factors VIIa, VIIIa, IXa, Xa, XIa, and XIIa were depressed, and PT and aPTT were prolonged. In another study,⁶² AT activity was assessed in cats inoculated intraperitoneally with FIP virus. Although coagulation screening test results indicated that all cats had DIC, AT activity 4 days after inoculation was within or above the reference range in all but one cat.⁶² These studies prove that DIC can be induced by experimental inoculation with FIP; however, the results also suggest that low-grade DIC may be present in some cats with naturally acquired FIP. In another retrospective study⁵⁵ that evaluated clotting times and AT activity in cats with naturally acquired diseases, DIC was diagnosed in 10 of 85 cats; all 10 cats had low AT activity. Because there is no gold standard test for the diagnosis of DIC in cats, it is possible that many feline DIC cases are missed and that the prevalence of feline DIC is higher than reported.

Plasma D-dimer and Fibrin Degradation Product Concentrations

D-dimers are products of cross-linked fibrin degradation. Factor XIIIa catalyzes the γ -chain cross-linkage of adjacent terminal domains (D-domains) of fibrin monomers.^{61,64,65} The D-dimer epitope is exposed when fibrin is lysed by plasmin. Thus, the presence of D-dimers is evidence of the combined actions of thrombin, factor XIIIa, and plasmin and is specific for the combined presence of coagulation and fibrinolysis (physiologic or pathologic). In contrast, an increase in FDPs is not specific evidence of active coagulation because FDPs include both fibrin and fibrinogen degradation products and thus may be increased exclusively by plasmin activity on fibrinogen. Increased FDPs do, however, prove that active fibrinolysis is present. D-dimers may be increased in dogs with non-DIC conditions associated with coagulation and fibrinolysis,^{58,61} including orthopedic surgery, neoplasia, and internal hemorrhage; thus, an increase in D-dimers alone cannot be regarded as confirmation of DIC.^{64,66–68}

Table 1. Laboratory Screening Tests for DIC*

Parameter/ Test	Early Hypercoagulable Phase	Clinical Manifestation Phase
Platelet count	=↓	↓
Schistocytosis	None	↑
PT	=↓	↑
aPTT	=↓	↑
Activated clotting time	=↓	↑
AT activity	=↓	↓
Fibrinogen	↓=↑ ^a	↓
FDP	=↓	↑
D-dimer	=↓	↑
Total protein C	=↓	↓
TAT	↑	↓=↑
PAP	↑	=↓

*Laboratory results should always be interpreted with caution and in light of the history and clinical signs because an abnormal result from any single test is not specific for the diagnosis of DIC. These tests are not very sensitive markers of DIC, and they may yield normal results in the early hypercoagulable stage of DIC. A positive diagnosis of DIC should rely on at least three abnormal laboratory test results along with compatible clinical signs of DIC. Serial monitoring of laboratory test results to assess the trends in patients suspected of having DIC is useful.

^aDepends on the underlying disease.

= Within normal limits; ↑ increased or prolonged; ↓ decreased or shortened.

TAT = thrombin-antithrombin complex

Several D-dimer assays have been evaluated in the diagnosis of DIC in veterinary medicine.^{61,64–68} Preliminary validation trials in canine patients have shown sensitivities and specificities ranging from 76% to 100% and 77% to 97%, respectively, with sensitivity largely dependent on the methodology and cutoff points used.^{61,64,67} The reference interval for canine D-dimers was established at 0.02 to 0.28 $\mu\text{g/mL}$ and 0.08 to 0.39 $\mu\text{g/mL}$ in two studies of healthy dogs.^{61,67} One study evaluated the use of latex-agglutination and immunoturbidimetric D-dimer assays and serum and plasma FDP assays in 20 dogs with DIC, using the high cutoff point of 0.39 $\mu\text{g/mL}$.⁶¹ The sensitivity of the latex-agglutination D-dimer assay was superior to that of immunoturbidimetry

(100% and 65%, respectively); both assays had equal specificity (97%). Compared with the serum and plasma FDP assays, the latex-agglutination assay had similar sensitivity (85% to 100%) and specificity (90% to 100%).⁶¹ Another study⁶⁴ evaluated a canine-specific D-dimer point-of-care test kit in healthy controls and dogs with DIC, thromboembolic disease, and hemorrhage. In this study, all healthy dogs had negative test results, while all dogs with DIC had positive results.⁶⁴

Results from recent studies support the use of D-dimer assays in the diagnosis of DIC, combined with evaluation of the history, a complete physical examination, and other traditional laboratory coagulation tests.^{61,67-69} Although human D-dimer assays have been validated as reliable and accurate in dogs,⁶¹ further research is needed to determine their true sensitivity and specificity in different phases of canine DIC as well as in feline DIC. Some authors have recommended that FDPs and D-dimers be assessed in combination to improve the diagnosis of DIC in dogs.⁶⁶ In one study,⁷⁰ reference intervals for D-dimers were established in healthy cats as 0.09 to 0.32 $\mu\text{g/mL}$; however, in another study,⁷¹ the same immunoturbidimetric test (STA-Liatest D-DI, Diagnostica Stago, Parsippany, NJ) was found to be not useful for the diagnosis of feline DIC.

Plasma Fibrinogen Concentration

The plasma fibrinogen concentration can be high, normal, or low in DIC and therefore is an insensitive marker for DIC.²⁰ A poor sensitivity of 0.8% was reported in dogs with DIC.⁶⁹ Hyperfibrinogenemia may be present in a variety of conditions other than DIC, including pregnancy and inflammation. Hypofibrinogenemia is considered specific for DIC in human patients⁷²; however, Wada and colleagues associated a poor prognosis with hyperfibrinogenemia in human leukemia and lymphoma patients with DIC.²⁰ They suggested that the combination of hyperfibrinogenemia and decreased fibrinolysis was among the factors leading to the increased prevalence of multiorgan failure observed in these patients, resulting in a higher death rate.²⁰ Because DIC is secondary to other diseases, opposing trends may coexist. Inflammation induces an increase in plasma fibrinogen, while consumption through coagulation and degradation by plasmin lead to a decrease.

Schistocytosis

The presence of schistocytes in blood smears has been studied in dogs with DIC. In one study,²⁸ schistocytosis

was recorded in 71% of the dogs; however, in a larger study of 252 dogs,⁷³ this abnormality was present in only 10%. Schistocytosis was observed in 61% of 101 cats with DIC in one retrospective study.⁴⁴ Schistocytes form in non-DIC conditions as well and thus should not be considered specific to DIC.⁵⁷

Other Tests

Other tests that are used in human medicine for the diagnosis and monitoring of DIC have recently been evaluated in veterinary medicine. Their use in canine and feline DIC is expected to grow.

Protein C Assay

APC down-regulates thrombin activity by irreversibly inhibiting factors Va and VIIIa.^{31,55} In DIC, the generation of APC is drastically reduced by a decrease in the thrombomodulin expression on endothelial cells, whereas the production of procoagulant proteases is increased.⁷⁴ Measurement of total protein C levels has been used in septic human patients to detect hypercoagulable states.² Combining measurement of protein C with routine tests was recently shown to improve recognition of portosystemic shunts, hepatic failure, and severe hepatobiliary disease in dogs.⁷⁵ Decreased protein C levels signified a grave prognosis when coupled with hyperbilirubinemia and low AT activity in hepatic failure.

Fibrinopeptide A Assay

When thrombin is generated during coagulation, fibrinopeptides A and B (FPA and FPB) are cleaved from fibrinogen, leaving behind fibrin monomers that later polymerize into fibrin through the action of factor XIIIa.⁵⁸ An FPA assay can, therefore, serve as a reliable marker of actual thrombin generation and “real-time” activity. FPA and FPB levels may be increased due to conditions other than DIC, including other micro- and macrovascular thrombotic events and advanced age,⁵⁸ or by other enzymes that cleave FPA.⁷⁶ In humans, FPA levels are increased in patients with DIC, deep vein thrombosis, pulmonary thromboembolism, myocardial or cerebral infarction, advanced neoplasia, or diabetes mellitus.⁷⁶ Measurement of FPA is complicated by its very short half-life (4 min in humans) and the potential for false-positive results from improper sampling and handling techniques. In humans, an ELISA or radioimmunoassay is used; these assays might be species specific. Their application in veterinary species has not been validated. Among several other abnormalities of

hemostasis, increased FPA levels were found in dogs undergoing experimental whole-body hyperthermia.⁷⁷

Plasmin- α_2 -Antiplasmin Complex Assay

α_2 -Antiplasmin, also known as α_2 -plasmin inhibitor, is one of the main inhibitors of fibrinolysis. Direct measurement of plasmin concentration is difficult because α_2 -antiplasmin rapidly complexes with plasmin. PAP complex levels can be measured by either ELISA or radioimmunoassay. PAP concentration is a good indicator of the activity of the fibrinolytic system (e.g., plasmin) and the degree of depletion of its main inhibitor (α_2 -antiplasmin).⁷⁸ During the onset of DIC, PAP levels are markedly increased; with remission, they are expected to decrease.^{19,58} This test has not been validated in veterinary species; however, injection of tissue plasminogen activator has led to increased PAP concentrations in dogs.⁷⁹

Thrombin-Antithrombin Complex Assay

In a manner similar to the formation of PAP, thrombin creates a stable complex with its inhibitor, AT (thrombin-antithrombin [TAT]). Because the half-life of thrombin is so short, thrombin concentration cannot be measured directly. TAT levels can be used to monitor ongoing activation of thrombin in patients predisposed to hypercoagulable states, such as sepsis. TAT levels determined by human-specific ELISA⁴³ have been vali-

thrombocytopenia, increased fibrolysis, and hypercoagulability.⁸² TEG has been used in septic human patients to identify the hypercoagulable state that precedes the clinically recognizable phase of DIC.⁸³ In veterinary medicine, TEG has been evaluated in a number of studies in dogs and cats with parvoviral enteritis as well as in healthy dogs.⁸⁴⁻⁸⁶ A 2005 study concluded that TEG monitoring of veterinary patients may be promising and that its use warrants further study.⁸⁷ In a 2007 study that evaluated the efficacy of low-molecular-weight heparin (LMWH) and unfractionated heparin (UFH) in healthy cats, reference intervals were established for all TEG parameters.⁸⁸

Transmittance Waveform Charts

Transmittance waveform charts profile light transmittance changes of standard coagulation assays, such as PT and aPTT.⁸⁹ Analysis and characterization of these data provide qualitative and quantitative information that cannot be obtained from clotting times alone. In human medicine, a biphasic aPTT waveform has been found to have high specificity and sensitivity for DIC.^{90,91} Furthermore, the degree of the waveform abnormality has been found to correlate with the severity of the hemostatic dysfunction, assisting in monitoring and allowing a prediction of the progression from nonovert to overt DIC.⁸⁹ This technique may improve

There is no single specific laboratory test for the diagnosis of disseminated intravascular coagulation.

dated and used in experimental canine models⁸⁰ and have proved to be increased in canine neoplasia.⁸¹ Recently, an antibody sandwich ELISA TAT test (Enzygnost TAT micro, Dade Behring Marburg, GmBH, Marburg, Germany) has been used in healthy cats and in cats with asymptomatic hypertrophic cardiomyopathy. A reference range for cats has been established at 2.0 to 20.0 $\mu\text{g/L}$.⁷⁰

Thromboelastography

Thromboelastography (TEG) characterizes the coagulation function by recording a tracing that represents blood clot creation and breakdown. The tracing is a sum of the interactions between coagulation factors, platelets, fibrin, fibrinolysis, and time. Different TEG patterns have been identified in a variety of hemostatic disorders, including coagulation factor deficiencies,

the diagnosis of DIC, allowing targeted therapeutic intervention early in the progression of the syndrome.⁹⁰

TREATMENT

Treatment should be instituted immediately when a diagnosis of DIC is established or a high index of suspicion exists.⁹² Removing or eliminating the precipitating cause constitutes the cornerstone and the main therapeutic goal for patients with DIC. The wide variety of underlying disorders makes the therapeutic approach to DIC particularly difficult.⁹³ Precipitating causes that can be treated and possibly eliminated include primary hemangiosarcoma and other tumors (surgical excision), lymphoma (chemotherapy), sepsis and bacterial infections (appropriate antimicrobial treatment), snakebites (specific antivenom), heatstroke (early appropriate cooling), and immune-mediated hemolytic anemia

(immunosuppression). However, the cause can rarely be eliminated within a short time.

The treatment aims for DIC in dogs and cats include the following:

- Impeding and possibly stopping intravascular coagulation and hemorrhage
- Maintaining good parenchymal organ perfusion
- Preventing secondary complications

Replacement therapy is the mainstay for the treatment of DIC.⁹³ A dual approach of blood component therapy and heparin administration is used to halt intravascular coagulation.

Blood Component Therapy

Fresh plasma (FP) or fresh frozen plasma (FFP) is administered to replace the consumed coagulation factors. At least 30 to 50 mL/kg/day is administered, initially at a rate of 10 mL/kg/hr and then at a rate of 2 mL/kg/hr. Alternatively, fresh whole blood can be administered as a source of coagulation factors and inhibitors and platelets. FP/FFP administration is aimed at halting the consumption of platelets, coagulation factors, and inhibitors (e.g., AT, α_2 -macroglobulin) by arresting the ongoing hemorrhagic and coagulation processes.

Heparin Administration

Heparin may be administered during the peracute hypercoagulable phase, when PT and aPTT are shortened, and if AT activity is at least 80%. It can also be administered after FP/FFP administration, but only when laboratory coagulation test results are normal.

The veterinary literature lacks prospective placebo-controlled studies on the use of heparin in DIC. Clinical reports and retrospective studies do not clearly indicate whether heparin use is beneficial. The effects of heparin may vary depending on the underlying cause and stage of DIC.¹⁸ Various uncontrolled studies have shown positive effects, no effect, or negative effects of heparin treatment^{54,94-96}; therefore, its use in patients with DIC is still under debate.

Heparin enhances thrombin and factor Xa inactivation through activation of AT inhibitory actions and, therefore, is ineffective when AT plasma activity is insufficient. Because AT activity in DIC is usually low⁹⁷ (as a result of consumption and, possibly, inactivation), it is advisable to provide the patient with sufficient quantities of AT, most efficiently through

blood component replacement. In a single study of dogs with different coagulopathies, FFP therapy (10 to 15 mL/kg q12h) did not result in increased plasma AT activity.⁹⁶

Heparin also inhibits coagulation by inducing the release of glycosaminoglycan-bound TFPI in the microvasculature into the circulation.⁹⁸ When coagulation is triggered by bacterial lipopolysaccharides in patients with sepsis, enhancement of TFPI activity represents an upstream anticoagulant action that is even more specific than that of AT.⁹⁵

To the best of our knowledge, there are no controlled prospective studies determining the appropriate heparin dose for DIC in veterinary patients or even substantiating its use in these cases. Extrapolation from the human literature is difficult because human patients at risk for DIC are generally also at high risk for deep vein thrombosis. Consequently, they are usually treated with aggressive heparin prophylaxis for deep vein thrombosis. This is generally not an issue in canine and feline patients. Controlled studies are difficult to conduct because DIC is not a primary disease, and manifestation and prognosis vary widely in accordance with the underlying disease. Several authors have, however, proposed that patients with DIC be given sodium heparin at 50 to 100 IU/kg SC q8h.^{5,99} This dose should be adjusted based on monitoring of aPTT and AT activity, with the aim of prolonging the aPTT by up to 30% above the upper reference interval in a hypercoagulable state. Such a value may also be achieved through replacement and supportive therapy alone and should be maintained through laboratory monitoring and heparin administration as needed.⁵

Low-Molecular-Weight Heparin Versus Unfractionated Heparin

LMWH, which is composed of heparin fractions with molecular weights of 4000 to 8000 daltons,⁹⁴ was found to be more advantageous than UFH in dampening activated coagulation in humans.¹⁰⁰ In human patients with endotoxemia, it has been shown to significantly reduce mortality.^{46,100,101} In a double-blinded, controlled study in human DIC patients, LMWH was more beneficial than UFH in decreasing bleeding complications.¹⁰⁰

UFH binds to AT, resulting in a conformation change of AT that leads to greatly enhanced inhibition of many coagulation factors (e.g., thrombin, Xa, XIa, XIIa, IXa). Because of its smaller molecular size, LMWH, unlike UFH, cannot simultaneously bind to AT and thrombin;

therefore, LMWH inhibits thrombin to a lesser extent.^{95,102,103} However, compared with UFH, LMWH has greater affinity for, and enhanced inhibition of, factor Xa.¹⁰⁴ LMWH also has a lesser tendency to bind to macrophages, plasma proteins, and platelets, accounting for its limited hepatic clearance, prolonged half-life, and better bioavailability.¹⁰⁵ In humans, LMWH has been found to have a two- to fourfold longer half-life than UFH, with greater bioavailability and more predictable anticoagulant effects.⁴⁶ In addition, compared with UFH, the likelihood of developing heparin-induced thrombocytopenia is reduced when LMWH is used.^{46,106}

Studies in dogs and cats have shown that LMWH is well tolerated by both species.^{88,105,107,108} A study evaluating the pharmacokinetics and pharmacodynamics of UFH in healthy dogs¹⁰⁹ showed that maximal antifactor Xa (aXa) activity after subcutaneous administration of 200 IU/kg of UFH was 0.56 aXa IU/mL and that this peak was reached within approximately 2 hours. In another study in dogs, subcutaneous administration of the same dose of LMWH resulted in a peak activity of

the inactivation of exogenous bovine factor Xa by AT in the presence of naturally occurring plasma antagonists. Chromogenic aXa assays, in which the plasma sample reacts with bovine factor Xa and AT in the presence of chromogen, are considered by many to be the gold standard tests for clinical monitoring of UFH or LMWH therapy.¹¹¹ However, Kovacs et al¹¹¹ showed that clinically significant differences exist between commercial chromogenic aXa assays. A recent study of healthy cats compared the pharmacokinetics and the effects of LMWH and UFH on several laboratory tests evaluating hemostasis.⁸⁸ There were no significant differences between UFH and two brands of LMWH (dalteparin and enoxaparin) in aXa activity at 4 hours after injection. However, all UFH-treated cats were above the therapeutic target aXa activity and showed hypocoagulability by TEG at 4 hours after treatment, while no dalteparin-treated cats and only two of five enoxaparin-treated cats achieved the therapeutic target aXa activity. The authors of the study concluded that based on the pharmacokinetics demonstrated in this study, cats have

The treatment goals are correction of the primary disease, prevention of intravascular coagulation and microthromboses, cessation of hemorrhage, maintenance of adequate parenchymal organ perfusion, and prevention of secondary complications.

0.9 aXa IU/mL within 3 hours.¹⁰⁵ A third study¹¹⁰ conducted in dogs with experimentally induced DIC showed that high doses of LMWH are required to interrupt the consumption reaction. A loading dose of 20 aXa IU/kg IV of LMWH followed by a continuous rate infusion (CRI) of 16.7 aXa IU/kg/hr of LMWH was found to be too low to halt the consumption reaction; however, a double loading dose of 40 aXa IU/kg IV of LMWH followed by a CRI of 33.3 aXa IU/kg/hr of LMWH was able to halt intravascular coagulation. This second dose resulted in a maximal aXa activity of 0.63 to 0.9 aXa IU/mL.

Monitoring Heparin Therapy

LMWH therapy cannot be adequately monitored with conventional coagulation tests such as PT and aPTT. Instead, aXa activity in patients receiving LMWH should be monitored with assays such as the Heptest assay or chromogenic aXa assays.^{104,105} The Heptest assay measures the ability of heparin to catalyze

rapid absorption and elimination kinetics with LMWH therapy and thus require higher LMWH doses and more frequent administration to achieve a therapeutic target aXa activity of 0.5 to 1.0 U/mL.⁸⁸

In our hospital, heparin use in patients with DIC is limited to patients in the early hypercoagulable phase of DIC with an aPTT prolongation of not more than 30% of the upper reference interval and adequate ($\geq 80\%$) plasma AT levels. Heparin is given along with FP transfusion. Although studies comparing the use of UFH with that of LMWH in dogs and cats with DIC have yet to be published, we currently recommend LMWH because of its above-mentioned advantages over UFH. However, aXa activity monitoring may not be readily available compared with aPTT testing.

Recently Described Treatment Modalities in Human Patients

Novel treatments have recently been proposed in human medicine. Some are under experimental evalua-

tion, while others are in use. The future will tell which, if any, will find their way into veterinary medicine.

Antithrombin Therapy

AT is considered to be the primary inhibitor of circulating thrombin, and AT levels are considerably reduced in DIC.¹¹² The administration of high doses of AT (100 IU/kg/day) to achieve supraphysiologic concentrations has been shown to reduce sepsis-related mortality in animal models.¹¹³ By comparison, the estimated AT level found in FFP (based on extrapolations from humans and our laboratory experience) is approximately 1 IU/mL. Recent studies^{113,114} have shown that AT has antiinflammatory properties that may further justify its use in the treatment of DIC. Several studies in human patients have shown that AT administration improved several coagulation parameters and organ functions.^{53,115} How-

Thrombomodulin therapy may be beneficial in DIC as a sole treatment with no APC transfusion.¹¹⁹ Thrombomodulin had a beneficial effect on coagulation in humans and animals and appeared to reduce pulmonary vascular injury and leukocyte accumulation.^{94,120} These effects were not dependent on thrombomodulin's thrombin-binding properties but were probably mediated through an increase in APC.^{94,119}

Interleukin-10 and Anti-Tumor Necrosis Factor Antibodies

Tissue inflammation has been proposed as an important mechanism in DIC associated with sepsis or major trauma. Administration of recombinant interleukin-10, an antiinflammatory cytokine, has been shown to completely nullify the endotoxin-induced effects on coagulation.¹²¹ Similarly, the use of monoclonal anti-TNF antibodies has

Disseminated intravascular coagulation is relatively common in dogs and uncommon in cats.

ever, in a phase III clinical trial in patients with severe sepsis, no survival advantage was found when a combination of high-dose AT and heparin was administered.¹¹⁶ Patients who received AT therapy alone showed a tendency toward increased survival.¹¹⁶ Future studies will indicate if high-dose AT treatment is indeed beneficial.

Activated Protein C and Thrombomodulin

Infusion of APC and thrombomodulin has been shown to prevent DIC and mortality in animal models of sepsis.^{53,115} Several trials in human patients have evaluated the usefulness of APC in sepsis-induced DIC.^{115,117,118} In one trial, a combination of human recombinant APC and thrombomodulin demonstrated benefits in patients with DIC.¹¹⁵ In another human trial, transfusion of concentrated APC limited leukocyte activation, cytokine elaboration, and microvascular coagulation and prevented organ damage.⁴⁷ In a phase III clinical trial, patients with severe sepsis showed improved survival when treated with recombinant human APC.¹¹⁸ These results led to the acceptance of APC treatment in certain human patients with severe sepsis. However, treatment with APC also caused an increased bleeding tendency. Although APC is available, it is very expensive and has the potential to cause antigenic reactions because it is a recombinant human protein.

shown a significant benefit in septic patients.⁴⁵ In this respect, the antiinflammatory effects of APC, including the modulation of TNF- α , interleukin-6, and interleukin-8 levels, may also be beneficial to patients with DIC.⁴⁷

PROGNOSIS

The prognosis of patients with DIC is guarded to poor, depending on the underlying disease, phase and severity of DIC, and patient's age and status. Early diagnosis and treatment are important factors in the outcome.¹⁹

In humans, high plasma fibrinogen levels are associated with organ failure and low fibrinogen levels with an increased risk for bleeding, both indicating a poor prognosis.²⁰ Several clinical studies in humans with sepsis have demonstrated that low levels of AT and protein C are also associated with a poor outcome.¹²²⁻¹²⁴

In animal studies, restoration of AT levels has been associated with improved outcome in terms of diminished occurrence of organ failure and a reduction in mortality.^{125,126} Total clotting time and AT activity were found to be highly reliable indicators for prognosis, and if both are out of the reference range 48 hours after initiation of therapy, a poor prognosis can be established.⁵⁴

CONCLUSION

DIC is a dynamic, secondary, acquired syndrome associated with variable primary triggers and clinical presen-

tations, and its diagnosis is complex. Because there is no uniformly accepted gold standard test, the diagnosis of DIC should be based on the history and clinical signs as well as the results of several serial diagnostic laboratory tests. Feline DIC is much less commonly diagnosed than canine DIC and thus has not been as extensively studied; differences in the clinical signs and diagnostic parameters are apparent and should be recognized when diagnosing DIC in cats. Novel, specific laboratory tests and newer therapeutic modalities that are available or are being scrutinized in human medicine will gradually reach veterinary practice. With time, these new tools are expected to improve the understanding of the pathophysiology, diagnosis, and treatment of DIC in dogs and cats.

REFERENCES

- Brooks M. Coagulopathies and thrombosis. In: Ettinger SJ, Feldman EC, eds. *Textbook of Veterinary Internal Medicine*. 5th ed. Philadelphia: WB Saunders; 2000:1829-1841.
- de Laforcade AM, Freeman LM, Shaw SP, et al. Hemostatic changes in dogs with naturally occurring sepsis. *J Vet Intern Med* 2003;17(5):674-679.
- Weiss DJ, Rashid J. The sepsis-coagulant axis: a review. *J Vet Intern Med* 1998;12(5):317-324.
- Kirby R, Rudloff E. Acquired coagulopathy VI: disseminated intravascular coagulation. In: Schalm OW, Feldman BF, Zinkl JG, Jain NC, eds. *Schalm's Veterinary Hematology*. 5th ed. Philadelphia: Lippincott Williams & Wilkins; 2000:581-587.
- Feldman BF, Kirby R, Caldin M. Recognition and treatment of disseminated intravascular coagulation. In: Bonagura JD, ed. *Kirk's Current Veterinary Therapy XIII: Small Animal Practice*. Philadelphia: WB Saunders; 2000:190-194.
- Levi M, de Jonge E, van der Poll T, et al. Disseminated intravascular coagulation. *Thromb Haemost* 1999;82(2):695-705.
- Couto CG. Disseminated intravascular coagulation in dogs and cats. *Vet Med* 1999;547-553.
- Bateman SW, Mathews KA, Abrams-Ogg ACG. Disseminated intravascular coagulation in dogs: review of the literature. *J Vet Emerg Crit Care* 1998;8(1):29-45.
- Brotman DJ, Deitcher SR, Lip GYH, et al. Virchow's triad revisited. *South Med J* 2004;97(2):213-214.
- Hammer AS, Couto CG, Swardson C, et al. Hemostatic abnormalities in dogs with hemangiosarcoma. *J Vet Intern Med* 1991;5(1):11-14.
- Majumdar G. Idiopathic chronic DIC controlled with low-molecular-weight heparin. *Blood Coagul Fibrin* 1996;7(1):97-98.
- Bruchim Y, Klement E, Saragusty J, et al. Heat stroke in dogs: a retrospective study of 54 cases (1999-2004) and analysis of risk factors for death. *J Vet Intern Med* 2006;20(1):38-46.
- Maruyama H, Miura T, Sakai M, et al. The incidence of disseminated intravascular coagulation in dogs with malignant tumor. *J Vet Med Sci* 2004;66(5):573-575.
- Millis DL, Hauptman JG, Fulton RB. Abnormal hemostatic profiles of gastric necrosis in canine gastric dilatation-volvulus. *Vet Surg* 1993;22(2):93-97.
- Segev G, Shipov A, Klement E, et al. *Vipera palaestinae* envenomation in 327 dogs: a retrospective cohort study and analysis of risk factors for mortality. *Toxicon* 2004;43(6):691-699.
- Scott-Moncrieff JC, Treadwell NG, McCullough SM, et al. Hemostatic abnormalities in dogs with primary immune-mediated hemolytic anemia. *JAAHA* 2001;37(3):220-227.
- Stockhaus C, Kohn B, Rudolph R, et al. Correlation of haemostatic abnormalities with tumour stage and characteristics in dogs with mammary carcinoma. *J Small Anim Pract* 1999;40(7):326-331.
- Levi M, ten Cate H. Disseminated intravascular coagulation. *N Engl J Med* 1999;341(8):586-592.
- Wada H. Disseminated intravascular coagulation. *Clin Chim Acta* 2004;344(1-2):13-21.
- Wada H, Mori Y, Okabayashi K, et al. High plasma fibrinogen level is associated with poor clinical outcome in DIC patients. *Am J Hematol* 2003;72(1):1-7.
- Esmon CT. Inflammation and thrombosis. *J Thromb Haemost* 2003;1(7):1343-1348.
- Okajima K. Regulation of inflammatory responses by natural anticoagulants. *Immunol Rev* 2001;184(1):258-274.
- Opal SM, Kessler CM, Roemisch J, et al. Antithrombin, heparin, and heparan sulfate. *Crit Care Med* 2002;30 (suppl 5):S325-S331.
- Levi M, de Jonge E, van der Poll T. Rationale for restoration of physiological anticoagulant pathways in patients with sepsis and disseminated intravascular coagulation. *Crit Care Med* 2001;29(suppl 7):S90-S94.
- Klein NJ, Levin M, Strobel S, et al. Degradation of glycosaminoglycans and fibronectin on endotoxin-stimulated endothelium by adherent neutrophils: relationship to CD11b/CD18 and L-selectin expression. *J Infect Dis* 1993;167(4):890-898.
- Jagneaux T, Taylor DE, Kantrow SP. Coagulation in sepsis. *Am J Med Sci* 2004;328(4):196-204.
- Levi M, ten Cate H, Bauer KA, et al. Inhibition of endotoxin-induced activation of coagulation and fibrinolysis by pentoxifylline or by a monoclonal anti-tissue factor antibody in chimpanzees. *J Clin Invest* 1994;93(1):114-120.
- Feldman BF, Madewell BR, O'Neill S. Disseminated intravascular coagulation: antithrombin, plasminogen, and coagulation abnormalities in 41 dogs. *JAVMA* 1981;179(2):151-154.
- Levi M, van der Poll T, Buller HR. Bidirectional relation between inflammation and coagulation. *Circulation* 2004;109(22):2698-2704.
- Alberio L, Safa O, Clemetson KJ, et al. Surface expression and functional characterization of alpha-granule factor V in human platelets: effects of ionophore A23187, thrombin, collagen, and convulxin. *Blood* 2000;95:1694-1702.
- Burstein SA. Cytokines, platelet production and hemostasis. *Platelets* 1997;8(2-3):93-104.
- Suffredini AF, Harpel PC, Parrillo JE. Promotion and subsequent inhibition of plasminogen activation after administration of intravenous endotoxin to normal subjects. *N Engl J Med* 1989;320(18):1165-1172.
- Couto CG. Clinical approach to the bleeding dog or cat. *Vet Med* 1999:450-459.
- Bouchama A, Bridy F, Hammami MM, et al. Activation of coagulation and fibrinolysis in heatstroke. *Thromb Haemost* 1996;76(6):909-915.
- Diehl KA, Crawford E, Shinko PD, et al. Alterations in hemostasis associated with hyperthermia in a canine model. *Am J Hematol* 2000;64(4):262-270.
- Gando S, Nakanishi Y, Tede I. Cytokines and plasminogen activator inhibitor-1 in post trauma disseminated intravascular coagulation: relationship to multiple organ dysfunction syndrome. *Crit Care Med* 1995;23(11):1835-1842.
- Nossel HL. Relative proteolysis of the fibrinogen B beta chain by thrombin and plasmin as a determinant of thrombosis. *Nature* 1981;291(5811):165-167.
- Gando S, Kameue T, Nanzaki S, et al. Disseminated intravascular coagulation is a frequent complication of systemic inflammatory response syndrome. *Thromb Haemost* 1996;75(2):224-228.
- Dauguschies A, Rupp U, Rommel M. Blood clotting disorders during experimental sarcocystiosis in calves. *Int J Parasitol* 1998;28(8):1187-1194.
- Dugernier T, Laterre P-F, Reynaert M, et al. Compartmentalization of the protease-antiprotease balance in early severe acute pancreatitis. *Pancreas* 2005;31(2):168-173.
- Bick RL. Disseminated intravascular coagulation and related syndromes: a clinical review. *Semin Thromb Hemost* 1988;14(4):299-338.
- Slappendel RJ. Disseminated intravascular coagulation. *Vet Clin North Am Small Anim Pract* 1988;18(1):169-184.
- Song HS, Kim HK, Song JW. Measurement of thrombus precursor protein in septic patients with disseminated intravascular coagulation and liver disease. *Haematologica* 2002;87(10):1062-1067.
- Peterson JL, Couto CG, Wellman ML. Hemostatic disorders in cats: a retrospective study and review of the literature. *J Vet Intern Med* 1995;9(5):298-303.
- Reinhart K, Karzai W. Anti-tumor necrosis factor therapy in sepsis: update on clinical trials and lessons learned. *Crit Care Med* 2001;29(7 suppl 1):S121-S125.

46. Weitz JI. Low-molecular-weight heparins. *N Engl J Med* 1997;337(10):688-699.
47. Esmon CT. Protein C anticoagulant pathway and its role in controlling microvascular thrombosis and inflammation. *Crit Care Med* 2001;29(7 suppl 1):S48-S52.
48. High KA. Antithrombin III, protein C, and protein S. Naturally occurring anticoagulant proteins. *Arch Path Lab Med* 1988;112(1):28-36.
49. Giudici D, Baudo F, Palareti G, et al. Antithrombin replacement in patients with sepsis and septic shock. *Haematologica* 1999;84(5):452-460.
50. Conway EM, Rosenberg RD. Tumor necrosis factor suppresses transcription of the thrombomodulin gene in endothelial cells. *Mol Cell Biol* 1988;8(12):5588-5592.
51. Fukudome K, Esmon CT. Identification, cloning, and regulation of a novel endothelial cell protein C/activated protein C receptor. *J Biol Chem* 1994;269(42):26486-26491.
52. Madden RM, Ward M, Marlar RA. Protein C activity levels in endotoxin-induced disseminated intravascular coagulation in a dog model. *Thromb Res* 1989;55(3):297-307.
53. Taylor Jr FB, Chang A, Esmon CT, et al. Protein C prevents the coagulopathic and lethal effects of *Escherichia coli* infusion in the baboon. *J Clin Invest* 1987;79(3):918-925.
54. Vlasin M, Rauser P, Fichtel T, et al. Disseminated intravascular coagulopathy of the dog. *Acta Vet Brno* 2004;74(4):497-505.
55. Thomas JS, Green RA. Clotting times and antithrombin III activity in cats with naturally developing diseases: 85 cases (1984-1994). *JAVMA* 1998;213(9):1290-1295.
56. Bateman SW, Mathews KA, Abrams-Ogg AC, et al. Diagnosis of disseminated intravascular coagulation in dogs admitted to an intensive care unit. *JAVMA* 1999;215(6):798-804.
57. Bateman SW, Mathews KA, Abrams-Ogg AC, et al. Evaluation of point-of-care tests for diagnosis of disseminated intravascular coagulation in dogs admitted to an intensive care unit. *JAVMA* 1999;215(6):805-810.
58. Bick RL, Arun B, Frenkel EP. Disseminated intravascular coagulation. *Haemostasis* 1999;29(2-3):111-134.
59. Bakhshi S, Arya LS. Diagnosis and treatment of disseminated intravascular coagulation. *Indian Pediatr* 2003;40(8):721-730.
60. Wada H, Gabazza EC, Asakura H, et al. Comparison of diagnostic criteria for disseminated intravascular coagulation (DIC): diagnostic criteria of the International Society of Thrombosis and Hemostasis (ISTH) and of the Japanese Ministry of Health and Welfare for overt DIC. *Am J Hematol* 2003;74(1):17-22.
61. Caldin M, Furlanello T, Lubas G. Validation of an immunoturbidimetric D-dimer assay in canine citrated plasma. *Vet Clin Pathol* 2000;29(2):51-54.
62. Boudreaux M, Weiss R, Cox N, et al. Evaluation of antithrombin-III activity as a coindicator of disseminated intravascular coagulation in cats with induced feline infectious peritonitis virus infection. *Am J Vet Res* 1989;50(11):1910-1913.
63. Weiss RC, Dodds WJ, Scott FW. Disseminated intravascular coagulation in experimentally induced feline infectious peritonitis. *Am J Vet Res* 1980;41(5):663-671.
64. Griffin A, Callan MB, Shofer FS, et al. Evaluation of a canine D-dimer point-of-care test kit for use in samples obtained from dogs with disseminated intravascular coagulation, thromboembolic disease, and hemorrhage. *Am J Vet Res* 2003;64(12):1562-1569.
65. Nelson OL, Andreasen C. The utility of plasma D-dimer to identify thromboembolic disease in dogs. *J Vet Intern Med* 2003;17(6):830-834.
66. Stokol T. Plasma D-dimer for the diagnosis of thromboembolic disorders in dogs. *Vet Clin North Am Small Anim Pract* 2003;33(6):1419-1435.
67. Stokol T, Brooks MB, Erb HN, et al. D-dimer concentrations in healthy dogs and dogs with disseminated intravascular coagulation. *Am J Vet Res* 2000;61(4):393-398.
68. Monreal L. D-dimer as a new test for the diagnosis of DIC and thromboembolic disease. *J Vet Intern Med* 2003;17(6):757-759.
69. Hirschberger J, Regel A, Krieger S, et al. D-dimers and optimized prothrombin test for diagnosis of D.I.C. in dogs. *J Vet Intern Med* 2004;18(3):440.
70. Bédard C, Lanevski-Pietersma A, Dunn M. Evaluation of coagulation markers in the plasma of healthy cats and cats with asymptomatic hyperthrombotic cardiomyopathy. *Vet Clin Pathol* 2007;36(2):167-172.
71. Brazzell JL, Borjesson DL. Evaluation of plasma antithrombin activity and D-dimer concentration in populations of healthy cats, clinically ill cats and cats with cardiomyopathy. *Vet Clin Pathol* 2007;36(1):79-84.
72. Yu M, Nardella A, Pechet L. Screening tests of disseminated intravascular coagulation: guidelines for rapid and specific laboratory diagnosis. *Crit Care Med* 2000;28(6):1777-1780.
73. Ross SJ, Smith SA, Lekcharoensuk C. Disseminated intravascular coagulation (DIC) in dogs: 252 cases (1999-2000). *Proc 20th ACVIM Forum* 2002. Accessed October 2007 at <http://www.vin.com/Members/proceedings/Proceedings.plx?CID:ACVIM2002&PID=1746&Category=9380=VIN>.
74. Fujita M, Izutani W, Takahashi K. Protein C inhibitor as an anti-disseminated intravascular coagulation agent—mechanism and modification. *Curr Med Chem Cardiovasc Hematol Agents* 2004;2(1):21-27.
75. Toulza O, Center SA, Brooks MB, et al. Evaluation of plasma protein C activity for detection of hepatobiliary disease and portosystemic shunting in dogs. *JAVMA* 2006;229(11):1761-1771.
76. Tracy RP, Bovill EG. Fibrinopeptide A. In: Beutler E, ed. *Williams Hematology*. 5th ed. New York: McGraw-Hill; 1995:L96-L98.
77. Strother SV, Bull JM, Branham SA. Activation of coagulation during therapeutic whole body hyperthermia. *Thromb Res* 1986;43(3):353-360.
78. Mammen EF. Disseminated intravascular coagulation (DIC). *Clin Lab Sci* 2000;13(4):239-248.
79. Maki A, Shirato C, Ohguchi M, et al. Mechanism of rethrombosis after thrombolytic therapy: angioscopic findings and investigation of the coagulation system in dogs. *Angiology* 1998;49(6):447-453.
80. Ravanat C, Freund M, Dol F, et al. Cross-reactivity of human molecular markers for detection of prethrombotic states in various animal species. *Blood Coagul Fibrinolysis* 1995;6(5):446-455.
81. Maruyama H, Watari T, Miura T, et al. Plasma thrombin-antithrombin complex concentrations in dogs with malignant tumours. *Vet Rec* 2005;156(26):839-840.
82. Mallett SV, Cox DJ. Thrombelastography. *Brit J Anaesth* 1992;69(3):307-313.
83. Grant HW, Hadley GP. Prediction of neonatal sepsis by thromboelastography. *Pediatr Surg Int* 1997;12(4):289-292.
84. Kraft W. Thromboelastogram in healthy domestic cats and therapy of disseminated intravascular coagulation (DIC) in panleukopenia [in German]. *Berl Munch Tierarztl Wochenschr* 1973;86(20):394-396.
85. Otto CM, Rieser TM, Brooks MB, et al. Evidence of hypercoagulability in dogs with parvoviral enteritis. *JAVMA* 2000;217(10):1500-1504.
86. von Schaeuwen H. Thrombelastographic studies and thrombocyte count in dogs [in German]. *Berl Munch Tierarztl Wochenschr* 1971;84(17):324-328.
87. Donahue SM, Otto CM. Thromboelastography: a tool for measuring hypercoagulability, hypocoagulability, and fibrinolysis. *J Vet Emerg Crit Care* 2005;15(1):9-16.
88. Alwood AJ, Downend AB, Brooks MB, et al. Anticoagulant effects of low-molecular-weight heparins in healthy cats. *J Vet Intern Med* 2007;21(3):378-387.
89. Toh CH, Giles AR. Waveform analysis of clotting test optical profiles in the diagnosis and management of disseminated intravascular coagulation (DIC). *Clin Lab Haematol* 2002;24(6):321-327.
90. Toh CH. Transmittance waveform of routine coagulation tests is a sensitive and specific method for diagnosing non-overt disseminated intravascular coagulation. *Blood Rev* 2002;16(suppl 1):S11-S14.
91. Downey C, Kazmi R, Toh CH. Early identification and prognostic implications in disseminated intravascular coagulation through transmittance waveform analysis. *Thromb Haemost* 1998;80(1):65-69.
92. Norman KE. Alternative treatments for disseminated intravascular coagulation. *Drug News Perspect* 2004;17(4):243-250.
93. Franchini M, Manzato F. Update of the treatment of disseminated intravascular coagulation. *Hematology* 2004;9(2):81-85.
94. de Jonge E, Levi M, Stoutenbeek CP, et al. Current drug treatment strategies for disseminated intravascular coagulation. *Drugs* 1998;55(6):767-777.
95. Pernerstorfer T, Hollenstein U, Hansen J-B, et al. Heparin blunts endotoxin-induced coagulation activation. *Circulation* 1999;100(25):2485-2490.
96. Rozanski EA, Hughes D, Scotti M, et al. The effect of heparin and fresh frozen plasma on plasma antithrombin III activity, prothrombin time and activated partial and thromboplastin time in critically ill dogs. *J Vet Emerg Crit Care* 2001;11(1):15-21.

97. Williamson LH. Antithrombin III: a natural anticoagulant. *Compend Contin Educ Pract Vet* 1991;100(13):100-106.
98. Abraham E, Reinhart K, Opal S, et al. Efficacy and safety of tifacogin (recombinant tissue factor pathway inhibitor) in severe sepsis: a randomized controlled trial. *JAMA* 2003;290(2):238-247.
99. Aiello S, Mays A. *The Merck Veterinary Manual*. 8th ed. Philadelphia: National Publishing; 1998:XXXV.
100. Sakuragawa N, Hasegawa H, Maki M, et al. Clinical evaluation of low-molecular-weight heparin (FR-860) on disseminated intravascular coagulation (DIC)—a multicenter co-operative double-blind trial in comparison with heparin. *Thromb Res* 1993;72(6):475-500.
101. Feige K, Schwartzwald CC, Bombeli T. Comparison of unfractionated and low molecular weight heparin for prophylaxis of coagulopathies in 52 horses with colic: a randomized double-blind clinical trial. *Equine Vet J* 2003;35(5):506-513.
102. Hirsh J, Warkentin TE, Shaughnessy SG, et al. Heparin and low-molecular-weight heparin mechanisms of action, pharmacokinetics, dosing, monitoring, efficacy, and safety. *Chest* 2001;119 (suppl 1):64S-94S.
103. Hirsh J, Raschke R. Heparin and low-molecular-weight heparin: the seventh ACCP Conference on Antithrombotic and Thrombolytic Therapy. *Chest* 2004;126(3 suppl):188S-203S.
104. Hoppensteadt DA, Jeske WP, Walenga JM, et al. Laboratory monitoring of pentasaccharide in a dog model of hemodialysis. *Thromb Res* 1999;96(2):115-124.
105. Mischke R, Grebe S. The correlation between plasma anti-factor Xa activity and haemostatic tests in healthy dogs, following the administration of a low molecular weight heparin. *Res Vet Sci* 2000;69(3):241-247.
106. Prandoni P, Siragusa S, Girolami B, et al. The incidence of heparin-induced thrombocytopenia in medical patients treated with low-molecular-weight heparin: a prospective cohort study. *Blood* 2005;106(9):3049-3054.
107. Mischke R, Grebe S, Jacobs C, et al. Amidolytic heparin activity and values for several hemostatic variables after repeated subcutaneous administration of high doses of a low molecular weight heparin in healthy dogs. *Am J Vet Res* 2001;62(4):595-598.
108. Smith CE, Rozanski EA, Freeman LM, et al. Use of low molecular weight heparin in cats: 57 cases (1999–2003). *JAVMA* 2004;225(8):1237-1241.
109. Diquelou A, Barbaste C, Gabaig AM, et al. Pharmacokinetics and pharmacodynamics of a therapeutic dose of unfractionated heparin (200 U/kg) administered subcutaneously or intravenously to healthy dogs. *Vet Clin Pathol* 2005;34(3):237-242.
110. Mischke R, Fehr M, Nolte I. Efficacy of low molecular weight heparin in a canine model of thromboplastin-induced acute disseminated intravascular coagulation. *Res Vet Sci* 2005;79(1):69-76.
111. Kovacs MJ, Keeney M, Mackinnon K, et al. Three different chromogenic methods do not give equivalent anti-Xa levels for patients on therapeutic low molecular weight heparin (dalteparin) or unfractionated heparin. *Clin Lab Haematol* 1999;21(1):55-60.
112. Giudici D, Baudo F, Palareti G, et al. Antithrombin replacement in patients with sepsis and severe shock. *Haematologica* 1999;84:452-460.
113. Inthorn D, Hoffmann JN, Hartl WH, et al. Effect of antithrombin III supplementation on inflammatory response in patients with severe sepsis. *Shock* 1998;10(2):90-96.
114. Okajima K, Uchiba M. The anti-inflammatory properties of antithrombin III: new therapeutic implications. *Semin Thromb Hemost* 1998;24(1):27-32.
115. Maruyama I. Recombinant thrombomodulin and activated protein C in the treatment of disseminated intravascular coagulation. *Thromb Haemost* 1999;82(2):718-721.
116. Warren BL, Eid A, Singer P, et al. High-dose antithrombin III in severe sepsis: a randomized controlled trial. *JAMA* 2001;286(15):1869-1878.
117. Vincent J-L, Angus DC, Artigas A, et al. Effects of drotrecogin alfa (activated) on organ dysfunction in the PROWESS trial. *Crit Care Med* 2003; 31(3):834-840.
118. Bernard GR, Vincent J-L, Laterre P-F, et al. Efficacy and safety of recombinant human activated protein C for severe sepsis. *N Engl J Med* 2001;344(10):699-709.
119. Uchiba M, Okajima K, Murakami K, et al. Effect of human urinary thrombomodulin on endotoxin-induced intravascular coagulation and pulmonary vascular injury in rats. *Am J Hematol* 1997;54(2):118-123.
120. Uchiba M, Okajima K, Murakami K, et al. Recombinant thrombomodulin prevents endotoxin-induced lung injury in rats by inhibiting leukocyte activation. *Am J Physiol* 1996;271(3 Pt 1):L470-L475.
121. Pajkrt D, van der Poll T, Levi M, et al. Interleukin-10 inhibits activation of coagulation and fibrinolysis during human endotoxemia. *Blood* 1997;89(8):2701-2705.
122. Fourrier F, Chopin C, Goudemand J, et al. Septic shock, multiple organ failure, and disseminated intravascular coagulation. Compared patterns of antithrombin III, protein C, and protein S deficiencies. *Chest* 1992;101(3): 816-823.
123. Mesters RM, Helterbrand J, Utterback BG, et al. Prognostic value of protein C concentrations in neutropenic patients at high risk of severe septic complications. *Crit Care Med* 2000;26(7):2209-2216.
124. Fisher Jr CJ, Yan SB. Protein C levels as a prognostic indicator of outcome in sepsis and related diseases. *Crit Care Med* 2000;28(9 suppl):S49-S56.
125. Kessler CM, Tang Z, Jacobs HM, et al. The suprapharmacologic dosing of antithrombin concentrate for *Staphylococcus aureus*-induced disseminated intravascular coagulation in guinea pigs: substantial reduction in mortality and morbidity. *Blood* 1997;89(12):4393-4401.
126. Minnema MC, Chang ACK, Jansen PM, et al. Recombinant human antithrombin III improves survival and attenuates inflammatory responses in baboons lethally challenged with *Escherichia coli*. *Blood* 2000;95(4):1117-1123.

CE TEST



The Auburn University College of Veterinary Medicine approves this article for 2 contact hours of continuing education credit. **Subscribers may take individual CE tests or sign up for our annual CE program.** Those who wish to apply this credit to fulfill state relicensure requirements should consult their respective state authorities regarding the applicability of this program.

1. D-dimer is a product of

- platelets.
- fibrinogen.
- cross-linked fibrin degradation.
- fibrin monomers.

2. In DIC, fibrinogen concentrations can be

- higher than normal.
- lower than normal.
- normal.
- any of the above

3. Increased D-dimer levels occur in patients

- with DIC.
- with thromboembolism.
- after orthopedic surgery.
- all of the above

4. Which statement regarding DIC is incorrect?

- Clinical signs are different in cats and dogs.
- Chronic DIC may be silent.
- Clinical signs of DIC always include spontaneous bleeding.
- DIC is not a primary disease.

5. Which statement regarding DIC in cats is true?

- a. DIC is a rare complication in cats.
- b. Hypofibrinogenemia is common.
- c. Bleeding is common.
- d. Cats present with clinical signs similar to those in dogs.

6. Bleeding in DIC is due to

- a. depletion of coagulation factors.
- b. excess FDPs.
- c. uncontrolled coagulation.
- d. all of the above

7. In DIC, formation of microthrombi is due to

- a. fibrin deposition.
- b. increased AT activity.
- c. protein C activation.
- d. a and b

8. In canine DIC, AT activity

- a. is mostly decreased.
- b. is mostly increased.
- c. is mostly associated with protein C.
- d. can be decreased, increased, or unchanged.

9. Heparin treatment in patients with DIC is

- a. recommended to stop coagulation in all phases of DIC.
- b. contraindicated due to increased risk of bleeding.
- c. useful only in the presence of sufficient AT.
- d. useful only in the presence of sufficient thrombin.

10. Chronic DIC is common in patients with

- a. heatstroke and gastric dilatation–volvulus.
- b. immune-mediated hemolytic anemia and snakebite.
- c. malignancy and chronic disorders.
- d. anticoagulant intoxication and hemolytic transfusion reaction.