



Oesophageal strictures in cats associated with doxycycline therapy

Alexander James German BVSc, PhD, CertSAM, DipECVIM-CA, MRCVS^{1*},
Martha Jane Cannon BA, VetMB, DSAM (Feline), MRCVS^{1†},
Charlotte Dye BVM&S, CertSAM, MRCVS¹,
Malcolm John Booth BVSc, MRCVS²,
Geoffrey Robert Pearson BVM&S, PhD, MRCPATH, MRCVS¹,
Caroline Anne Reay BVSc, CertVR, MRCVS³,
Timothy John Gruffydd-Jones BVetMed, PhD, DipECVIM-CA, MRCVS¹

¹Department of Clinical Veterinary Science, University of Bristol, Langford House, Bristol BS40 5DU, UK

²Department of Veterinary Clinical Science and Animal Husbandry, Small Animal Hospital, Crown Street, Liverpool L7 7EX, UK

³The Blue Cross Animal's Hospital, 88-92 Merton High Street, London SW19 1BE, UK

Four cases of oesophageal stricture subsequent to doxycycline administration are reported. All cases were young to middle age (median age 3 years; range 1–7 years), and either domestic shorthair or domestic longhair breed. In all cases the predominant clinical sign was regurgitation, which developed at variable times after doxycycline administration. In all cases the reason for doxycycline use was treatment or prophylaxis of suspected infections (*Mycoplasma haemofelis*, *Chlamydophila felis* or *Bordetella bronchiseptica*), and the duration of therapy was variable. In one case the stricture was definitively diagnosed at post mortem examination, in the three other cases, definitive diagnosis was by endoscopy. Balloon dilation was successful in the three cases that were treated. This is the largest case series, to date, of oesophageal disease in cats associated with doxycycline administration. Caution should be exercised when administering oral medication to cats, especially doxycycline, and should be accompanied either by a water or food swallow.

© 2004 ESFM and AAEP. Published by Elsevier Ltd. All rights reserved.

Oesophagitis and oesophageal stricture formation are uncommon in cats and, in most previous reports, most commonly occur as a complication following general anaesthesia (Pearson et al 1978, Harai et al 1995, Galatos et al 2001, Leib et al 2001, Adamama-Moraitou et al 2002). Strictures usually result from granulation and scar tissue formation following ulceration caused by damage to the oesophageal mucosa (Kikendall 1991). In man, the retention of orally-administered medication is commonly implicated in the aetiology of oesophageal ulceration and oesophagitis (Jaspersen 2000), although subsequent stricture formation is uncommon. Whilst numerous medications

are implicated, tetracycline antibiotics are most common (Jaspersen 2000). In cats, oesophageal stricture has been reported as a complication of doxycycline therapy in six cases to date (Melendez et al 2000, Leib et al 2001, McGrotty and Knottenbelt 2002). This report describes a further four cats with oesophageal disease, presumed to be associated with doxycycline administration.

Materials and methods

Data collection

Information was compiled from four cases seen at the Department of Clinical Veterinary Science, University of Bristol (UOB; $n = 2$), the Department of Veterinary Clinical Sciences, University of Liverpool (UOL; $n = 1$) and the Blue Cross Animal's Hospital, Merton, London (BCAH;

*Corresponding author. Current address: University of Liverpool, Small Animal Hospital, Crown Street, Liverpool L7 7EX, UK. E-mail: ajgerman@liv.ac.uk

†Current address: Oxfordshire Cat Clinic, Ilges Lane, Cholsey, Oxon OX10 9PA, UK.

$n = 1$). A searchable computer database was not available at UOB, and cases were recruited (from referrals between September 1999 and September 2002), on the basis of case recall from individual clinicians. No cases were identified before this time, based on limited checks of the available records (histopathology database, radiographic database). A searchable computer database was available at UOL, enabling the records of all feline admissions between 1 January 2002 and 1 July 2003 to be examined. The BCAH case was identified after a telephone advice call between two of the authors (CR and TJGJ). A searchable computer database was not available at this centre and no attempt was made to trace similar cases.

For inclusion in the study, all cases required (1) evidence of prior administration of oral doxycycline, and (2) an oesophageal stricture documented either at endoscopy or at necropsy. For the purposes of the study, a stricture was defined as a narrowing of the oesophageal lumen due to the proliferation of fibrous tissue within the wall (Guilford and Strombeck 1996). For the cases diagnosed at endoscopy, diagnosis was based on visual inspection alone, whilst gross and microscopic pathological criteria were used when post mortem examination was performed. The degree of luminal narrowing required for inclusion was not specified. For all cases the details of signalment, history, diagnostic investigations, treatment and outcome were recorded.

Pathological studies

One cat (case 3; BCAH) was euthanased and a portion of the oesophagus associated with the stricture submitted for histopathological examination. The sample was fixed in 10% neutral buffered formalin, and embedded in paraffin wax. Sections were cut at 4 μm and stained with haematoxylin and eosin.

Results

Signalment and history

For the UOB, two cases were identified that fitted the inclusion criteria. In the same period, approximately 750 feline cases were referred. One other case (a 6-year-old, neutered male, domestic shorthair cat) was identified which had developed regurgitation after oral doxycycline therapy for *Mycoplasma haemofelis* infection. Although an oesophageal stricture was suspected, the owners

had refused further investigations. Therefore, this case was not included in the current study. Out of a total of 275 new cases referred to the UOL in the time period, one cat fitted the inclusion criteria.

The signalment and history for the four cases fitting the inclusion criteria are summarised in Table 1. Three of the cases were domestic shorthair, whilst the remaining case was a domestic longhair. Cats were young to middle age (median 3 years, range 1–7 years); three cats were neutered males, whilst one cat was a neutered female. General anaesthesia had not been performed in any of the cats in the 6 months before onset of clinical signs.

In all cases the history included treatment with doxycycline for clinical signs unrelated to alimentary tract disease. In three cats clinical signs included collapse, dyspnoea and pale mucous membranes. In all of these cases *M haemofelis* infection was suspected. Doxycycline had been administered before confirmation of the diagnosis. One cat (case 3) was presented to the referring veterinary surgeon with bilateral conjunctivitis and chemosis, and infection with *Chlamydophila felis* was suspected. Swabs were collected for laboratory diagnosis and treatment with topical chlortetracycline (Aureomycin Ophthalmic Ointment; Fort Dodge) and oral doxycycline (Ronaxan; Merial, Harlow, UK; 20 mg q 12 h) was administered. However, no respiratory viruses (feline herpesvirus or feline calicivirus) or *C felis* were documented. In the final case (case 4), the cat was initially presented with respiratory tract signs, eg, sneezing, nasal discharge and ocular discharge. Acute infectious upper respiratory tract disease was suspected and, doxycycline was administered to control secondary bacterial infection. In this case, otitis externa was also present, suspected to be secondary to *Otodectes* species infection.

Oesophageal disease was suspected in all cases based on the presence of regurgitation, although in one case the cat was initially thought to be vomiting. In all cases the regurgitation usually occurred immediately after eating. The owners reported no other clinical signs, and the clinical problem for which the doxycycline had been administered had resolved in all cases. Physical examination findings included poor body condition in two cases and mild dental calculus and gingivitis in a further case, but examination was unremarkable in the remaining two cases.

The median duration of therapy with doxycycline was 7 days (range = 1–28 days). The

Table 1. Summary of clinical information

Case	Signalment	Presenting complaint	Doxycycline therapy	Timing of therapy ¹	Other therapy	Diagnostic imaging	Endoscopy	Other	Therapy for stricture	Outcome
1	7, neutered male, domestic shorthair	Collapse, pale mucous membranes, suspected <i>M haemofelis</i>	7 days, 5 mg q 24 h PO	3–10 days	None	Fluoroscopy. Stricture at thoracic inlet	Stricture at thoracic inlet	Routine haematology, serum biochemistry, FeLV, FIV	Balloon dilation, twice at 48 h interval. Dexamethasone ⁸ , later sucralfate ⁹ , ranitidine ¹⁰	Free from clinical signs 20 months
2	2, neutered male, domestic shorthair	Collapse, dyspnoea, open-mouth breathing, suspected <i>M felis</i>	PO for 48 h (two 5 mg tablets)	9–10 days	None	Thoracic and abdominal radiography	Stricture 12 cm from oral cavity (heart base)	Routine haematology, serum biochemistry, FeLV, FIV, thoracic and abdominal radiography	Balloon dilation, four times at 48 h intervals. Dexamethasone ⁸ , later sucralfate ⁹ , ranitidine ¹⁰	Free from clinical signs 15 months
3	1, neutered female, domestic shorthair	Bilateral conjunctivitis and chemosis	20 mg q 12 h PO for 21 days	0–11 days	Chlortetracycline eye ointment ² (t), ketoprofen ³ (SC), metoclopramide ⁴ (SC), cimetidine syrup ⁵ (PO) amoxicillin/clavulanate ⁶ (SC then PO)	Barium swallow and radiography. Retention of barium in cranial thoracic oesophagus	Inconclusive	Post mortem examination	No specific therapy	Euthanased at owners request
4	3, neutered male, domestic longhair	Sneezing, nasal discharge, ocular discharge, concurrent otitis externa	25 mg, q12 h PO for 5 days	11–16 days	Chlortetracycline ² (t), aural therapy ⁷ (t)	Barium swallow with fluoroscopy/radiography and confirmed stricture at thoracic inlet	Stricture confirmed	None	Balloon dilation; two dilations 96 h apart. Sucralfate ⁹ , ranitidine ¹⁰	Free from clinical signs 12 months later

¹Timing of therapy prior to onset of regurgitation; ²Aureomycin Ophthalmic Ointment, Fort Dodge; ³Ketofen, Merial; ⁴Emequell, Pfizer; ⁵Tagamet, SmithKline Beecham; ⁶Synulox, Pfizer; ⁷Canaural ear drops, Leo; ⁸Dexedreson, Intervet; ⁹Antepsin, Wyeth; ¹⁰Zantac, Glaxo. PO = per os; SC = subcutaneous injection; t = topical. Cases 1 and 2 were seen at the University of Bristol, case 3 was seen at the Blue Cross Animal's Hospital, and case 4 was seen at The University of Liverpool.

relationship between the development of clinical signs and the timing of administration before the onset of clinical signs was variable (Table 1). However, in one cat only two doses of doxycycline had been given, approximately 10 days before the onset of regurgitation. In some cases other medications were also administered before stricture formation including topical chlortetracycline (Aureomycin eye ointment; $n = 2$), subcutaneous ketoprofen (Ketofen; Merial; $n = 1$), topical fucidin, framycetin, nystatin and prednisolone (Canaural ear drops; Leo, Princes Risborough, UK; $n = 1$). In addition, in one case (cat 3), oral clavulanate–potentiated amoxicillin (Synulox; Pfizer; Sandwich, UK) and oral cimetidine (Tagamet; SmithKline Beecham, Welwyn Garden City, UK) were administered subsequent to doxycycline therapy, and after clinical signs had developed.

Diagnostic investigations

In 2/4 cases, preliminary laboratory diagnostic investigations were performed, which included haematological and serum biochemical analysis, and testing for feline leukaemia virus (FeLV) antigen and feline immunodeficiency virus (FIV) antibody. Results were normal in all cats. Lateral plain thoracic radiography was also normal in all cases. Diagnostic imaging studies included a barium meal under fluoroscopic observation ($n = 2$), a barium meal with subsequent radiography ($n = 1$; case 3), and a barium meal with combined fluoroscopy and radiography ($n = 1$; case 4; Fig 1). Retention of barium was demonstrated cranial to a narrowing at the thoracic inlet

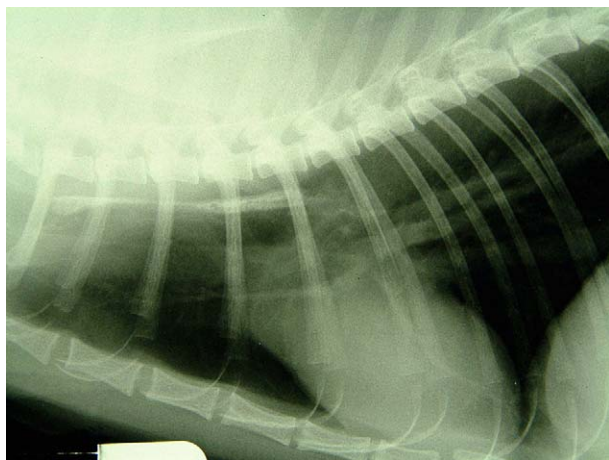

Fig 1. Right lateral thoracic radiograph from case 4, taken after fluoroscopic study. Barium is retained in the cranial thoracic oesophagus, to the level of the heart base.

($n = 2$), and at the level of the heart base or caudal thoracic oesophagus ($n = 2$; Fig 1). Endoscopy was performed in all cases and confirmed the presence of stricture in three cats (Fig 2), and it was not possible to pass the endoscope beyond the stricture. In the other case (case 3), endoscopy was inconclusive but the procedure had been performed early in the course of disease when under investigations for 'vomiting' rather than regurgitation. A barium swallow and radiographic assessment was performed 3 weeks later, and identified an oesophageal stricture. Further, a gross post mortem examination was eventually performed, which confirmed an oesophageal stricture at the level of the lower oesophagus.

The site was confirmed as the thoracic inlet ($n = 2$), and heart base or lower oesophagus ($n = 2$). In the three cases diagnosed at endoscopy, the degree of luminal narrowing caused by the stricture was not accurately recorded. However, in all cases it was not possible to pass the endoscope (insertion tube diameter 9 mm in all cases) through the stricture at the time of diagnosis.

Treatment and outcome

In one case (case 3), the cat was euthanased at the owners' request before obtaining a definitive diagnosis (eventually confirmed at post mortem examination); the exact timing of this in relation to the endoscopy and barium study was not clear from the records. Balloon dilation, under endoscopic guidance, was undertaken in the other three cases. In two cases (cases 1 and 2), four dilation procedures were performed at 2-day intervals. The stricture of the third case (case 4) required two dilation procedures, which were performed 4 days apart. For cases 1 and 2, an 8 cm length, 20 mm maximum diameter balloon catheter was used (exact product not known). For case 4, Microinvasive CRE balloon dilation catheters (Boston Scientific Corporation, Natick, USA; either 8 cm length \times 10 mm maximum diameter, or 8 cm length \times 20 mm maximum diameter; outside diameter dependent upon degree of inflation) were used at various stages of the procedure. The exact inflation pressure, duration of inflation and number of inflation/deflation cycles (at each dilation procedure) were not consistently recorded in any case.

A number of medications were administered including, oral ranitidine syrup (Zantac; Glaxo, Stockley Park, UK; $n = 3$) and oral sucralfate suspension (Antepsin; Chugai, London, UK;

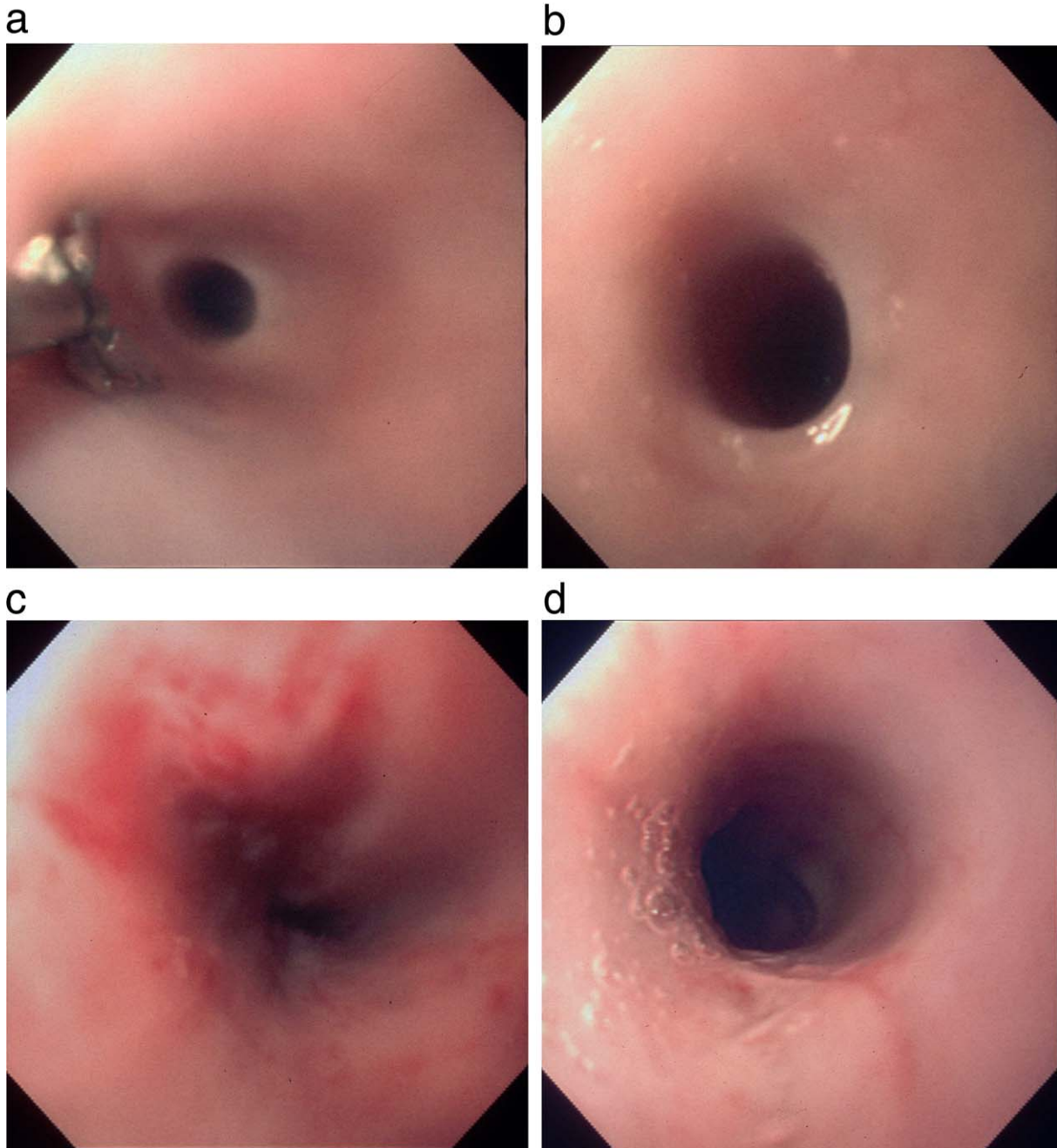


Fig 2. (a, b) Pre-treatment endoscopic view of the mid-oesophagus of cat 1, demonstrating a stricture. The endoscopic forceps in (a), allow an indirect estimate of size. (c) Appearance of stricture immediately after dilation procedure. (d) Appearance of stricture 24 h after the same dilation procedure; dilation was not repeated at this time.

$n = 3$), oral prednisolone ($n = 1$), parenteral dexamethasone (Dexadreson; Intervet, Cambridge, UK; $n = 2$) and parenteral metoclopramide (Emequell; Pfizer; $n = 1$). In all cats ranitidine and sucralfate were administered after discharge for between 10 and 14 days. Nutritional therapy was instigated in all cases, involving the feeding of liquefied convalescent diets. These three cats are currently free from

clinical signs, between 12 and 20 months after discharge.

Post mortem findings

On post mortem examination in case 3, significant changes were confined to the oesophagus. A focal area of narrowing of the lumen was evident at a point approximately two-thirds of the

distance between the oropharynx and the lower oesophageal sphincter. On opening the oesophagus at this point a 1.5×0.5 cm mucosal scar was observed.

Histopathological findings

In a section of the lower oesophagus adjacent to the lesion, the muscularis mucosae was intact and the lamina propria contained a moderate, predominantly lymphoid, inflammatory cell infiltrate. At the edge of the lesion the epithelium was hyperplastic (Fig 3); the epithelium in the centre of the lesion was flat, and the muscularis mucosae was replaced by fibrous tissue which was infiltrated by a mixed population of inflammatory cells (Fig 3).

Discussion

This report documents four cats that developed oesophageal strictures, in which a common factor was prior doxycycline administration. Given the complex case histories in most of these cats, it would be difficult to be certain that doxycycline was the cause of clinical signs. Nevertheless the only clear factor in common between these cases was the administration of doxycycline. Strictures were definitively diagnosed by endoscopy in three cases and at post mortem examination in the remaining case. It is of note that prior endoscopy in the latter case did not identify a stricture and, given the limited data available, the reason for this is not known. However, the initial clinical signs may have been related to oesophagitis, ulceration and associated oesophageal dysmotility, and a stricture may not

have been gross evident at this stage. Since mucosal healing can be quick, the oesophagitis may have resolved at the time of endoscopy, but the oesophageal motility may still have been compromised.

Drug-induced oesophageal disorders (DIOD) are common in humans; over 70 drugs are known to cause pill-induced oesophagitis, and antibacterials are implicated in over 50% of cases (Jaspersen 2000). There have been numerous reports of tetracycline-induced oesophageal injury in humans, and doxycycline is most commonly implicated (Bokey and Hugh 1975, Crowson et al 1976, Schneider 1977, Amendola and Spera 1985, Delpre et al 1989, Biller et al 1991). The incidence of DIOD in companion animals is not known, but there have been several recent reports of suspected doxycycline-induced oesophageal stricture formation in cats following treatment for naturally occurring diseases (Melendez et al 2000, Leib et al 2001, McGrotty and Knottenbelt 2002), and cats have previously been used in an experimental model for acid-induced and drug-induced oesophagitis (Carlborg and Densert 1980, Carlborg et al 1983, Geisinger et al 1990).

Doxycycline is a 6-desoxy tetracycline that is well absorbed following oral administration and has a longer half-life (approximately 20 h) than other tetracyclines (Lanza 1988). Studies in humans and animals have confirmed that the high acidity of the doxycycline solution, when dissolved, is the principal factor for their irritant effect. The acidity of various tetracycline derivatives varies depending on the tetracycline and its salt. Doxycycline hyclate produces a highly acidic solution whilst in comparison, a solution of doxycycline monohydrate is much less acidic (Lanza 1988). Further, doxycycline monohydrate is slower to dissolve in neutral solutions such as those encountered in the oesophageal lumen (Bogardus and Blackwood 1979). Therefore, doxycycline monohydrate has been associated with a lower frequency of development of oesophageal ulcers in man. The doxycycline preparation currently licensed for use in cats in the UK (Ronaxan) is a tablet-based preparation of the hyclate salt.

In humans, oesophageal ulceration, secondary to doxycycline therapy, is reported more commonly than stricture formation. The ulcers are usually single, focal and pinpoint, but can be circumferential or linear (Kikendall et al 1983). Circumferential strictures only occur after extensive and deep mucosal penetration. In contrast,

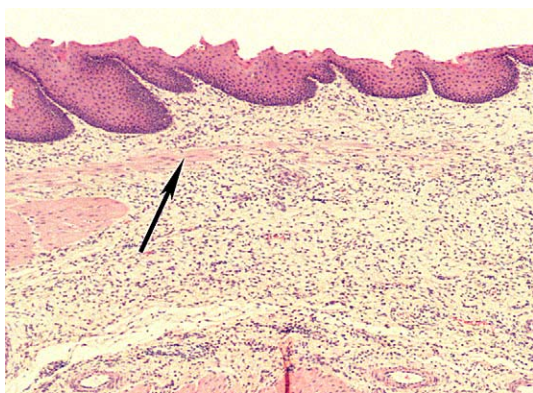


Fig 3. Oesophagus, cat (case 3). Epithelium is hyperplastic and the muscularis mucosae (arrow) is reduced. Fibrous tissue expands the lamina propria and submucosa. Haematoxylin and eosin $\times 50$.

strictures have been reported more commonly in cats, and this is most likely due to the fact that the early symptoms in humans (eg, odynophagia and mid-chest pain) are not recognised. Therefore, despite the fact that the current data would suggest the development of oesophageal strictures secondary to doxycycline therapy is uncommon, the true incidence of oesophageal disease (eg, oesophagitis, oesophageal ulceration and oesophageal strictures) may be underestimated.

In man, the site of oesophageal injury is usually the cranial oesophageal inlet or the region overlying the base of the heart; two sites of potential obstruction to the passage of an oral medication (Kikendall 1991). Similarly, in cases 1, 2 and 3 described here, the strictures appeared to be at the heart-base region of the thoracic oesophagus. Resected oesophageal strictures from human patients demonstrate full-thickness fibrosis (Bonavina et al 1987). Histopathology of lesions in experimental feline models of oesophageal injury demonstrates epithelial erosion and inflammation extending into the submucosa, and oesophageal wall thickening (Kikendall 1991). The insult causing the oesophageal stricture of case 3 had extended into the submucosa. Such changes would not necessarily be pathognomonic for strictures caused by doxycycline, and might have been the result of another disease process, eg, secondary to reflux oesophagitis after general anaesthesia (Barker et al 1993). In this regard, oesophageal damage from gastric reflux can extend as far as the pharynx (Barker et al 1993), and strictures have been reported in the cranial oesophagus and lower cervical region (Pearson et al 1978). Further, whilst the damage from gastric reflux is most often generalised, localised damage can occur (Pearson et al 1978). Given that general anaesthesia was performed in case 3, reflux oesophagitis is an alternative explanation. However, the anaesthetic was administered after the onset of clinical signs, and the association with doxycycline administration would therefore be more likely. Another possible explanation in this case would be that the oesophageal stricture had arisen secondary to damage from ketoprofen, since NSAIDs have been associated with oesophageal ulceration in humans (Jaspersen 2000). However, a causal association is again unlikely, given that this medication was administered subcutaneously, and was started after the onset of regurgitation. Clavulanate-potentiated amoxicillin and cimetidine were the only other drugs administered

orally, but therapy was instigated after the onset of clinical signs, and neither has previously been associated with oesophageal disease in any species. Nevertheless, the administration of any oral medication to a cat with an oesophageal injury might exacerbate clinical signs by mechanical abrasion. *Yersinia pestis* was a potential causative agent cited in a previous case series (Melendez et al 2000) but, whilst our cases were not assessed for the presence of such an infectious agent, any potential role in this series is unknown.

In humans, symptoms develop within 6–12 h and can persist for 3–4 weeks in severe cases (Lanza 1988). In most of the current cases, the exact time for stricture development could not be determined accurately since prolonged courses of treatment were often used, and the time of onset of clinical signs was not always recorded. Based on the available information in the present study, signs of regurgitation developed a minimum and maximum of 0 and 16 days, respectively, after doxycycline therapy. In one case, (case 2), the time between treatment and stricture formation was more easily established since only two treatments were administered. In this case it was 10 days before the regurgitation was documented. This is similar to the time course documented in previous reports (Melendez et al 2000, McGrotty and Knottenbelt 2002).

DIOD can potentially occur in any human patient swallowing a caustic pill, because moderate delay in pill transit is a common event even in people with normal oesophageal motility (Boyce 1998). In humans, the risk of pill retention increases with increasing age (Kikendall 1991), but there was no apparent age association either in the cats of this study, or in the previous reports (Melendez et al 2000, Leib et al 2001, McGrotty and Knottenbelt 2002). Other contributory factors in humans include supine position when swallowing the medication, decreased saliva production, insufficient fluid taken with pill, duration of contact with mucosa, and the presence of oesophageal obstruction, eg, by an enlarged left atrium, enlarged bronchial lymph nodes, or primary oesophageal disorders such as neoplasia, strictures or dysmotility (Kikendall 1991, Boyce 1998, Jaspersen 2000). Retention of medication is also more likely with capsules since they are more likely to stick to the mucosa.

In oesophageal transit studies in normal cats the passage of capsules was frequently prolonged, compared with tablets, and 'complete entrapment' (defined as retention for more than

4 h) was common (Graham et al 2000). However, feeding a small amount of food after capsule entrapment invariably led to immediate passage of the capsule into the stomach. Subsequent work has assessed the effect of administering water immediately after oral dosing (Westfall et al 2001). Transit times were significantly less for both capsules and tablets after water was administered, compared with when capsules or tablets were administered dry. Therefore, all oral medication administered to cats should be given either with food, or followed by a small amount of water (5 ml), given by syringe. Further, if oesophageal dysmotility is suspected, the patient should be held upright after administration. Alternatively, medication should be provided in liquid form or crushed and dispersed in fluid. Similar recommendations exist in humans (Jaspersen 2000).

Finally, doxycycline-induced oesophageal injury has not been reported in dogs. This might be the result of species differences in the structure and function of the oesophagus, either making pill retention less likely or the mucosa less prone to injury. However, it may also reflect differences in the frequency with which doxycycline is prescribed, and the methods of tablet administration. First, as the current case series has highlighted, doxycycline is frequently administered for treatment or prophylaxis of a number of specific feline infectious diseases including *C felis*, *M haemofelis*, and *Bordetella bronchiseptica*. *B bronchiseptica* is a common tetracycline-sensitive infection in dogs but doxycycline is less commonly used, possibly given that oxytetracycline is cheaper or that other antimicrobials (eg, fluoroquinolones) are preferred. Moreover, given the less fastidious feeding habits of dogs compared with cats, medication is easier to disguise in food and so rapid transit through the oesophagus would be expected.

In summary, oesophageal stricture formation can be a complication of doxycycline therapy in cats. Veterinary surgeons should be aware of this risk, and take steps to guard against the possibility of DIOD in cats.

Acknowledgements

The authors would like to thank the first-opinion veterinary surgeons for referring the cases, and Langford Veterinary Diagnostics, Department of Clinical Veterinary Science, University of Bristol, for help with haematology, bacteriology, microbiology and histopathology.

Radiographic studies were kindly performed by the diagnostic imaging services of the Universities of Bristol (cases 1 and 2) and Liverpool (case 4). AJG was supported by a clinical training scholarship funded by BSAVA Petsavers. MC and CD were both supported by clinical training scholarships from the Feline Advisory Bureau. We are grateful to John Connabear, University of Bristol Photography Department, for assistance with the photographic figures. Finally, the authors are grateful to Dr BF Warren for helpful comments.

References

- Adamama-Moraitou KK, Rallis TS, Prassinos NN, Galatos AD (2002) Benign esophageal stricture in the dog and cat: a retrospective study of 20 cases. *Canadian Journal of Veterinary Research* **66**, 55–59.
- Amendola MM, Spera TD (1985) Doxycycline-induced esophagitis. *Journal of the American Medical Association* **253**, 1009–1011.
- Barker IK, Van Dremmel AA, Palmer N (1993) The alimentary system. In: Jubb KVF, Kennedy PC, Palmer N (eds), *Pathology of Domestic Animals*. vol 2, (4th edn). New York: AC Press Inc., pp. 1–317.
- Billir JA, Flores A, Buie T, Mazor S, Katz AJ (1991) Tetracycline-induced esophagitis in adolescent patients. *Journal of Pediatrics* **120**, 144–145.
- Bogardus JB, Blackwood RK (1979) Dissolution rates of doxycycline free base and hydrochloride salts. *Journal of Pharmaceutical Science* **68**, 1183–1184.
- Bokey L, Hugh TB (1975) Oesophageal ulceration associated with doxycycline therapy. *Medical Journal of Australia* **1**, 236–237.
- Bonavina L, DeMeester TR, McChesney L, Schwizer W, Albertucci M, Bailey RT (1987) Drug-induced esophageal strictures. *Annals of Surgery* **206**, 173–183.
- Boyce HW (1998) Drug-induced esophageal damage: diseases of medical progress. *Gastrointestinal Endoscopy* **47**, 547–550.
- Carlborg B, Densert O (1980) Esophageal lesions caused by orally administered drugs. An experimental study in the cat. *European Journal of Surgery* **12**, 270–282.
- Carlborg B, Densert O, Linqvist C (1983) Tetracycline induced esophageal ulcers. A clinical and experimental study. *Laryngoscope* **93**, 184–187.
- Crowson TD, Head LH, Ferrante WA (1976) Esophageal ulcers associated with tetracycline therapy. *Journal of the American Medical Association* **235**, 2747–2748.
- Delpre G, Kadish U, Stahl B (1989) Induction of esophageal injuries by doxycycline and other pills: a frequent but preventable occurrence. *Digestive Diseases and Sciences* **34**, 797–800.
- Galatos AD, Savas I, Prassinos NN, Raptopoulos D (2001) Gastroesophageal reflux during thiopentone or propofol anaesthesia in the cat. *Journal of Veterinary Medicine* **48**, 287–294.
- Geisinger KR, Cassidy KT, Nardi R, Castell DO (1990) The histologic development of acid-induced esophagitis in the cat. *Modern Pathology* **3**, 619–624.
- Graham JP, Lipman AH, Newell SM, Roberts GD (2000) Esophageal transit of capsules in clinically

- normal cats. *American Journal of Veterinary Research* **51**, 655–657.
- Guilford WG, Strombeck (1996) Diseases of swallowing. In: Guilford WG, Center SA, Strombeck DR, Williams DA, Meyer DJ (eds), *Strombeck's Small Animal Gastroenterology* (3rd edn). Philadelphia, PA: WB Saunders Company, pp. 211–238.
- Harai BH, Johnson SE, Sherding RG (1995) Endoscopically guided balloon dilatation of benign esophageal strictures in 6 cats and 7 dogs. *Journal of Veterinary Internal Medicine* **9**, 332–335.
- Jaspersen D (2000) Drug-induced oesophageal disorders. *Drug Safety* **22**, 237–249.
- Kikendall JW (1991) Pill-induced esophageal injury. *Gastroenterology Clinics of North America* **20**, 835–846.
- Kikendall JW, Friedman AC, Oyewole MA, Fleischer D, Johnson LF (1983) Pill-induced esophageal injury: case reports and review of the medical literature. *Digestive Diseases and Sciences* **28**, 174–182.
- Lanza FL (1988) Esophageal ulceration produced by doxycycline. *Current Therapeutic Research* **44**, 475–484.
- Leib MS, Dinnel H, Ward DL, Reimer ME, Towell TL, Monroe WE (2001) Endoscopic balloon dilation of esophageal strictures in dogs and cats. *Journal of Veterinary Internal Medicine* **15**, 547–552.
- Melendez LD, Twedt DC, Wright M (2000) Suspected doxycycline-induced esophagitis with esophageal stricture formation in three cats. *Feline Practice* **28**, 10–12.
- McGrotty YL, Knottenbelt CM (2002) Oesophageal stricture in a cat due to administration of tetracyclines. *Journal of Small Animal Practice* **43**, 221–223.
- Pearson H, Darke PGG, Gibbs C, Kelly DF, Orr CM (1978) Reflux oesophagitis and stricture formation after anaesthesia: a review of seven cases in dogs and cats. *Journal of Small Animal Practice* **19**, 507–519.
- Schneider R (1977) Doxycycline esophageal ulcers. *American Journal of Digestive Diseases* **22**, 805–807.
- Westfall DS, Twedt DC, Steyn PF, Oberhauser EB, VanCleave JW (2001) Evaluation of esophageal transit of tablets and capsules in 30 cats. *Journal of Veterinary Internal Medicine* **15**, 467–470.

Available online at www.sciencedirect.com

