

Mesenteric volvulus in the dog: a retrospective study of 12 cases

Mesenteric volvulus was diagnosed in 12 dogs over a nine-year period. Each case was presented with abdominal distension and shock. Haematochezia, which is frequently reported in association with mesenteric volvulus, was present in only two of the dogs. The diagnosis, which in all cases was based on radiography, was followed by immediate treatment for shock and surgical intervention whenever possible. In five of the 12 cases, the volvulus was treated successfully and these patients survived. This indicates that the prognosis for mesenteric volvulus might be better than is currently believed, and immediate laparotomy is recommended if mesenteric volvulus is suspected.

G. JUNIUS, A. M. APPELDOORN AND
E. SCHRAUWEN

Journal of Small Animal Practice (2004)
45, 104–107

Dierenartsenpraktijk Plantijn,
Bosduifstraat 18/20, 2018 Antwerp,
Belgium

INTRODUCTION

Mesenteric, or intestinal, volvulus is a rare disorder in the dog involving intestinal rotation at the root of the mesentery, causing occlusion of the cranial mesenteric artery. Obstruction of this artery leads to ischaemia of the distal duodenum, jejunum, ileum, caecum, ascending colon and proximal descending colon (Evans and Christensen 1979). This ischaemia can result in bowel necrosis, toxin release and shock. The clinical signs of mesenteric volvulus include abdominal pain, abdominal distension, haematochezia, pale mucous membranes, tachycardia, weak pulses and, ultimately, death (Slatter 1993).

A specific cause for mesenteric volvulus in the dog is not usually evident, but it has been reported in association with treatment for worm infestation (Tvedten 1973), lymphocytic-plasmacytic enteritis and ileocolic carcinoma (Harvey and Rendano 1984, Nemzek and others 1993), pancreatic insufficiency (Westermarck and Rimaila-Pärnänen 1989), intussusception, parvoviral infection (Nemzek and others 1993), vigorous exercise, closed abdominal trauma, concurrent gastric dilatation-volvulus, and gastrointestinal foreign bodies (Harvey and Rendano 1984, Matushek and Cockshutt 1987).

Mesenteric volvulus is associated with

an extremely high mortality rate (Harvey and Rendano 1984, Westermarck and Rimaila-Pärnänen 1989, Shealy and Henderson 1992, Nemzek and others 1993, Cairo and others 1999). Nemzek and others (1993) reported the survival of one dog out of six cases, while Shealy and Henderson (1992) reported one survivor out of nine cases. In the present report, five of the 12 cases were treated successfully and survived. One of these cases has been described previously (Appeldoorn and Schrauwen 1995).

MATERIALS AND METHODS

The medical records of 12 dogs admitted to the authors' veterinary hospital with intestinal volvulus between 1992 and 2002 were reviewed. The diagnosis of mesenteric volvulus was confirmed at surgery or post-mortem examination. The data collated included signalment, history, clinical signs, radiographic findings, treatment and results.

RESULTS

Signalment

The breeds of dog involved were: Bernese mountain dog, bloodhound (two), Canadian shepherd dog, German shepherd dog (two), Great Dane (three), Labrador and mastino napolitano (two). There were eight males and four females with an age range of 10 months to nine years (median four years, nine months). The dogs are listed in Table 1.

History

The onset of illness was peracute to acute, with a duration of two to 12 hours before presentation, and no history of trauma in any of the dogs. Dogs 4, 6 and 11 had undergone a gastropexy for the treatment of gastric dilatation-volvulus (two years, one year and two months previously, respectively) before the mesenteric volvulus developed. Dog 11 had severe diarrhoea a few days before presentation.

Table 1. Signalment and outcome in 12 dogs with mesenteric volvulus

Case number	Breed	Age	Sex	Outcome
1	Canadian shepherd dog	4 years, 9 months	M	Euthanased during surgery due to extensive bowel necrosis
2	Labrador	9 years, 1 month	F	Euthanased without surgery
3	Mastino napolitano	6 years, 2 months	F	Alive
4	Bloodhound	5 years, 7 months	M	Died during surgery
5	Great Dane	6 years, 9 months	F	Euthanased during surgery due to extensive bowel necrosis
6	Mastino napolitano	2 years	M	Alive
7	Great Dane	7 years, 10 months	M	Alive
8	Bloodhound	3 years, 1 month	M	Died during surgery
9	Great Dane	3 years, 7 months	M	Euthanased without surgery
10	German shepherd dog	10 months	M	Alive
11	Bernese mountain dog	3 years, 10 months	F	Alive
12	German shepherd dog	3 years, 8 months	M	Euthanased during surgery due to extensive bowel necrosis

M Male, F Female

Clinical signs

Haematochezia was observed in dogs 1 and 3. Attempts to vomit and salivation were seen in dogs 5, 6 and 7. Abdominal distension, abdominal pain and rapid development of shock were noted in all dogs.

Radiographic findings

Abdominal radiography was performed in all dogs and was indicative of mesenteric volvulus, revealing severely distended gas-filled loops of small bowel, lying parallel to each other (Figs 1 and 2). Gastric dilatation-volvulus was also present in dogs 6 and 9.

Treatment

Initial treatment of the dogs consisted of supportive shock therapy with intravenous 0.9 per cent sodium chloride (Baxter) and clavulanate-potentiated amoxicillin (Augmentin; Glaxo SmithKline), followed by stomach intubation to relieve the abdominal pressure. Since this was not curative, radiography was performed and confirmed mesenteric volvulus in each case. Where permitted by the owner, immediate surgery was carried out, and was initiated within 30 minutes to one hour following presentation of the dog.

Dogs 2 and 9 were presented in severe shock and, since the owners refused

surgery, euthanasia was performed. Dogs 1, 5 and 12 had extensive necrosis of a large portion of the small bowel and were euthanased during surgery. Dogs 4 and 8 died during surgery.

In dog 11, a 1 m segment of necrotic jejunum was excised. In the remaining four dogs, derotation of the mesenteric root was followed by recovery of the circulation and motility of the intestine. These dogs recovered fully without enterectomy.

DISCUSSION

As in earlier reports, most of the dogs with mesenteric volvulus reported here were adult (median age four years, nine months) male, medium- to large-breed dogs. In most previous reports, German shepherd dogs have been observed to be the most commonly affected breed. In the present series, only two German shepherd dogs were seen, while this breed constitutes 5 per cent of the authors' hospital population. Conversely, the bloodhound (two cases), Great Dane (three cases) and mastino napolitano (two cases) seemed to be over-represented, since they only constitute 0.11 per cent, 0.97 per cent and 0.18 per cent, respectively, of the hospital population.

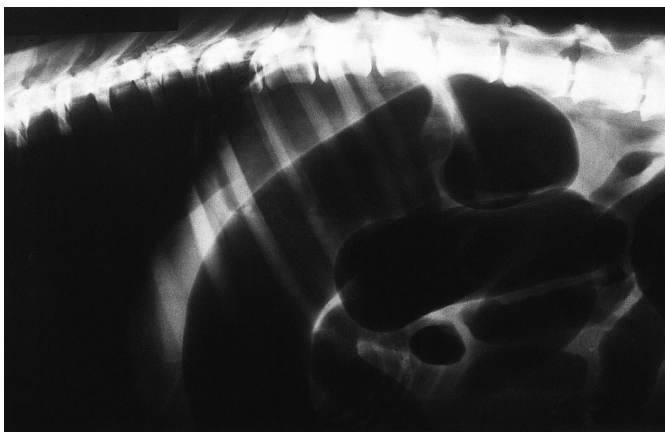


FIG 1. Radiograph of the abdomen of a dog which did not survive (case 5), showing severely distended gas-filled loops of small bowel, lying parallel to each other

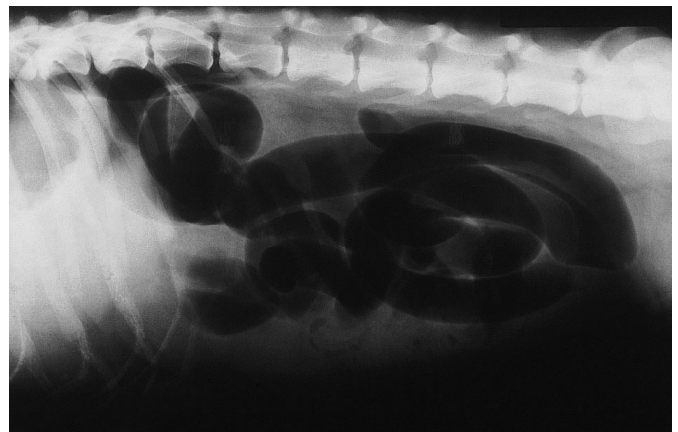


FIG 2. Radiograph of the abdomen of a survivor (case 6), likewise showing severely distended gas-filled loops of small bowel, lying parallel to each other

An acute onset of signs was common. The usual signs of weakness, recumbency, shock, abdominal pain and abdominal distension were present. Haematochezia, frequently reported in mesenteric volvulus cases (Shealy and Henderson 1992, Nemzek and others 1993), was only present in two dogs. The patients were initially treated as gastric dilatation-volvulus cases, with shock treatment and gastric decompression. As gastric intubation did not resolve the problem, radiographs were taken in each case. Evidence of gas and fluid intestinal distension suggested a diagnosis of mesenteric volvulus and, when the owner consented, prompt surgical intervention was instituted, leading to euthanasia or death in seven cases, and survival in five cases.

The number of cases surviving the mesenteric volvulus in this report is high when compared to other reports in the literature (Harvey and Rendano 1984, Westermarck and Rimaila-Pärnänen 1989, Shealy and Henderson 1992, Nemzek and others 1993, Cairo and others 1999). This is probably the result of the early surgical intervention, and the different breeds affected in the present study. The German shepherd dog is the most commonly affected breed, and nearly all reported cases (38 dogs) have died. In other breeds, higher survival rates have been reported: Great Dane (four cases), 50 per cent; mongrel dogs (three cases), 33 per cent; German shepherd dog cross (three cases), 66 per cent; dobermann (four cases), 100 per cent; small breed (three cases), 33 per cent (Parker and Presnell 1972, Castellano and others 1983, Harvey and Rendano 1984, Odendaal 1984, Marks 1986, Matushek and Cockshutt 1987, Seibold 1988, Carberry and others 1989, Stickle and Walshaw 1989, Westermarck and Rimaila-Pärnänen 1989, Camble and Page 1992, Shealy and Henderson 1992, Carberry and Flanders 1993, Kik and van der Linde-Sipman 1993, Nemzek and others 1993, Appeldoorn and Schrauwen 1995, Landwehr 1995, Cosenza 1996, Sentell 1997, Cairo and others 1999, Rahal and others 2000).

In other reports, surgery was often delayed for several hours, which may also account for the higher mortality rate. Where mesenteric volvulus is present for a more prolonged period, oedema of the intestinal wall, haemorrhage and epithelial sloughing occur. Strangulated loops become turgid and permeable and blood accumulates within the intestinal lumen. Within eight to 12 hours, the intestine reaches maximal distension and its colour changes to greenish-black (Ellison 1990, Cosenza 1996, Leib and Matz 1997). When the torsion persists, hypoxia of the bowel wall results in destruction of the mucosal barrier, and intestinal bacteria and toxins diffuse into the peritoneal cavity and enter the systemic circulation (Ellison 1990). Death then results from a combination of hypovolaemic, septic and toxic shock (Cosenza 1996).

Major tissue damage not only occurs during the period of ischaemia, but also when the ischaemia is relieved and the tissues are reperfused. The pathogenesis of this so-called reperfusion injury includes the release of oxygen-derived free radicals (Strombeck and Guilford 1996). These free radicals damage tissues by a wide variety of means including the initiation of microvascular damage by causing lipid peroxidation of endothelial cell membranes. The major sources of reperfusion-induced free radicals appear to be the tissue enzyme xanthine oxidase and neutrophil enzymes such as NADPH oxidase myeloperoxidase (Strombeck and Guilford 1996). Most of this injury occurs within the first five minutes of reperfusion.

The diagnosis of mesenteric volvulus is difficult because clinical signs are non-specific and the patient's condition deteriorates rapidly. If there is suspicion of mesenteric volvulus following radiography, the authors would recommend that an emergency laparotomy is performed. If prompt action is taken, it is possible that the prognosis for mesenteric volvulus might be more favourable than is currently believed. Premedication with oxyradical

scavengers before surgical derotation might also reduce reperfusion injury and increase survival.

Conclusions

Complete mesenteric volvulus is a rare disease with a grave prognosis, especially in the German shepherd dog. If a suspicion of mesenteric volvulus exists, in particular where there is typical radiological evidence of dilated small bowel loops, immediate exploratory laparotomy is advised. In cases where laparotomy is not delayed, a higher survival rate may be expected.

References

- APPELDOORN, A. M. & SCHRAUWEN, E. M. J. (1995) Mesenteric torsion in a dog: a survivor. *Vlaams Diergeneeskundig Tijdschrift* **64**, 62-63
- CAIRO, J., FONT, J., GORRAIZ, J., MARTIN, N. & PONS, C. (1999) Intestinal volvulus in dogs: a study of four clinical cases. *Journal of Small Animal Practice* **4**, 136-140
- CAMBLE, P. J. & PAGE, C. A. (1992) Mesenteric torsion in a toy dog. *Veterinary Record* **130**, 166-167
- CARBERRY, C. A. & FLANDERS, J. A. (1993) Cecal-colic volvulus in two dogs. *Veterinary Surgery* **22**, 225-228
- CARBERRY, C. A., HARVEY, H. J. & BLACKBURN, H. (1989) Small intestinal volvulus in a dog. *Compendium on Continuing Education for the Practicing Veterinarian* **11**, 1322-1323
- CASTELLANO, C., IDIART, J. & IBARGOYEN, G. (1983) Mesenteric torsion in a dog. *Veterinary Medicine* **78**, 1360-1362
- COSENZA, S. F. (1996) Recognising and treating mesenteric torsion in dogs. *Veterinary Medicine* **6**, 929-933
- ELLISON, G. W. (1990) Intestinal obstruction. In: *Disease Mechanisms in Small Animal Surgery*, 2nd edn. Ed M. J. Bojrab. Lea & Febiger, Philadelphia. pp 249-252
- EVANS, H. E. & CHRISTENSEN, G. C. (1979) Heart and arteries. In: *Miller's Anatomy of the Dog*, 2nd edn. Eds H. E. Evans and G. C. Christensen. W. B. Saunders, Philadelphia. pp 632-756
- HARVEY, H. J. & RENDANO, V. T. (1984) Small bowel volvulus in dogs: clinical observations. *Veterinary Surgery* **13**, 91-94
- KIK, M. J. L. & VAN DER LINDE-SIPMAN, J. S. (1993) Torsio mesenterialis bij de hond. *Tijdschrift voor Diergeneeskunde* **118**, 115-116
- LANDWEHR, K. (1995) Iatrogen hervorgenruferer volvulus mesenterialis jejuni et ilei bei einem hund. *Kleintierpraxis* **5**, 399-401
- LEIB, M. S. & MATZ, M. E. (1997) Diseases of the intestines. In: *Practical Small Animal Internal Medicine*. Eds M. S. Lieb and W. E. Monroe. W. B. Saunders, Philadelphia. pp 685-760
- MARKS, A. (1986) Torsion of the colon in a rough collie. *Veterinary Record* **118**, 400
- MATUSHEK, K. J. & COCKSHUTT, J. R. (1987) Mesenteric and gastric volvulus in a dog. *Journal of the American Veterinary Medical Association* **191**, 327-328
- NEMZEK, J. A., WALSHAW, R. & HAUPTMAN, J. G. (1993) Mesenteric volvulus in the dog: a retrospective study. *Journal of the American Animal Hospital*

- Association **29**, 357-361
- ODENDAAL, J. S. J. (1984) Volvulus van die dunderm in 'n hond. *Journal of the South African Veterinary Association* **55**, 123-124
- PARKER, W. M. & PRESNELL, K. R. (1972) Mesenteric torsion in the dog, two cases. *Canadian Veterinary Journal* **13**, 283-284
- RAHAL, S. C., GARIB, M. I., MAMPRIM, M. J. & TEIXEIRA, C. R. (2000) Mesenteric torsion in a dog. *Canadian Veterinary Journal* **41**, 710-711
- SEIBOLD, K. E. (1988) What is your diagnosis? *Journal of the American Veterinary Medical Association* **20**, 495-496
- SENTELL, R. (1997) There is an option for treating mesenteric torsion. *Veterinary Medicine* **92**, 22
- SHEALY, P. M. & HENDERSON, R. A. (1992) Canine intestinal volvulus: a report of nine new cases. *Veterinary Surgery* **21**, 15-19
- SLATTER, D. H. (1993) Small intestine. In: *Textbook of Small Animal Surgery*, 2nd edn. Ed D. H. Slatter. W. B. Saunders, Philadelphia. pp 593-612
- STICKLE, R. & WALSHAW, R. (1989) What is your diagnosis? *Journal of the American Veterinary Medical Association* **194**, 1631-1632
- STROMBECK, D. R. & GUILFORD, W. G. (1996) Miscellaneous disorders of the bowel, abdomen, and rectum. In: *Strombeck's Small Animal Gastroenterology*, 3rd edn. Eds W. G. Guilford, S. A. Center, D. R. Strombeck, D. A. Williams and D. J. Meyer. W. B. Saunders, Philadelphia. pp 503-518
- TVEDTEN, H. W. (1973) Fatal volvulus in a puppy. *Veterinary Medicine: Small Animal Clinic* **68**, 506-510
- WESTERMARCK, E. & RIMAILA-PÄRNÄNEN, E. (1989) Mesenteric torsion in dogs with exocrine pancreatic insufficiency: 21 cases (1978-1987). *Journal of the American Veterinary Medical Association* **145**, 1404-1406

© British Small Animal Veterinary Association. All rights reserved